IVUS and OCT

Rishi Puri MD, PhD, FRACP

Staff, Coronary & Structural Interventions
Associate Professor of Medicine
Medical Director, IVUS/Angiography Core Laboratory

Cleveland Clinic
Heart & Vascular Institute

C5Research
Cleveland Clinic Coordinating Center for Clinical Research

Cleveland Clinic

Disclosures

Within the past 12 months, I or my spouse/partner have had a financial interest, arrangement, or affiliation with the organization(s) listed below:

Affiliation/Financial Relationship	Company
Grant/Research Support	N/A
Consulting Fees/Honoraria	**Medtronic, Amgen, Sanofi**
Stock Shareholder/Equity	**Centerline Biomedical**
Royalty Income	N/A
Ownership/Founder	N/A
Intellectual Property Rights	N/A
Other Financial Benefit	N/A

Expanding world of invasive plaque imaging

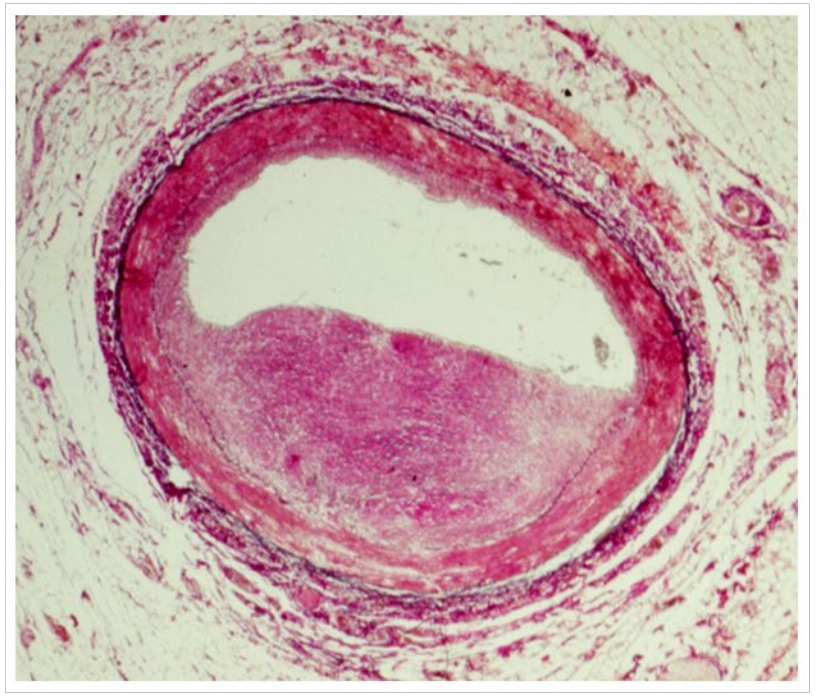

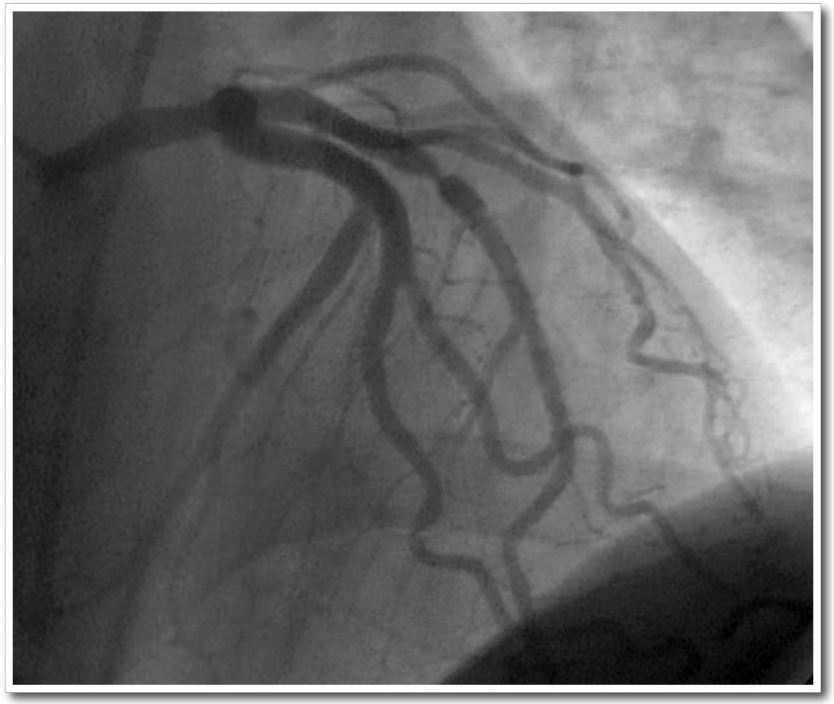

IVUS

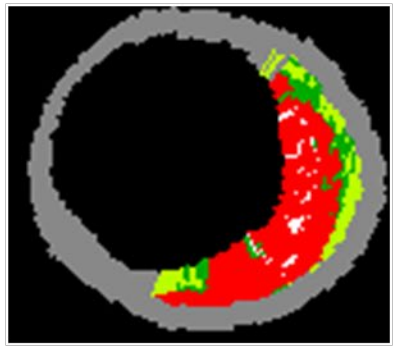

IVUS-VH

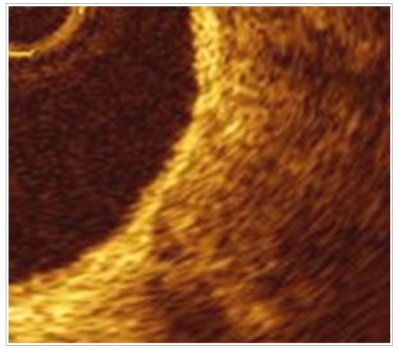

OCT



NIR Spectroscopy

Puri R. et al Nat Rev Cardiol 2011

Why do we use IVUS…? To Study the Vessel Wall

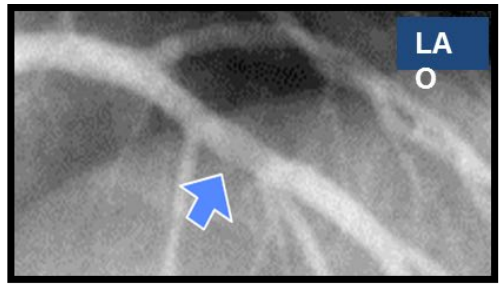

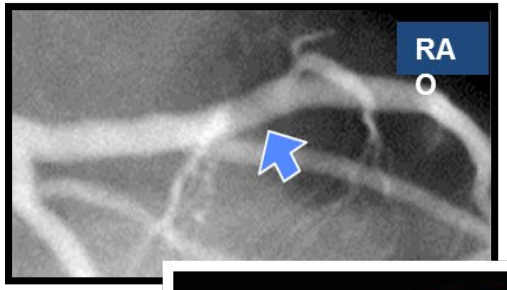

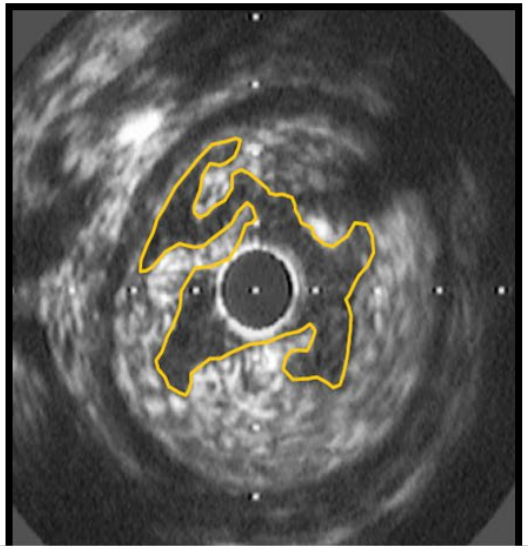

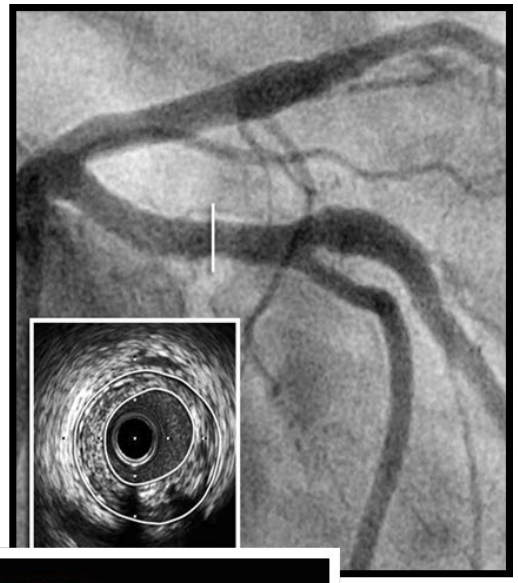

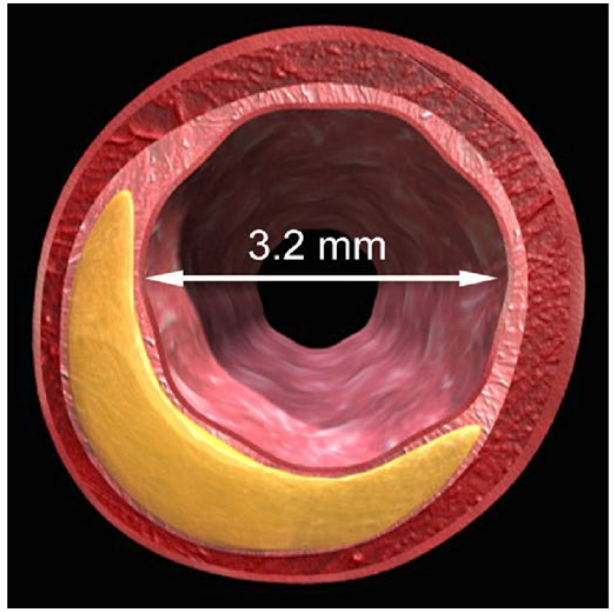

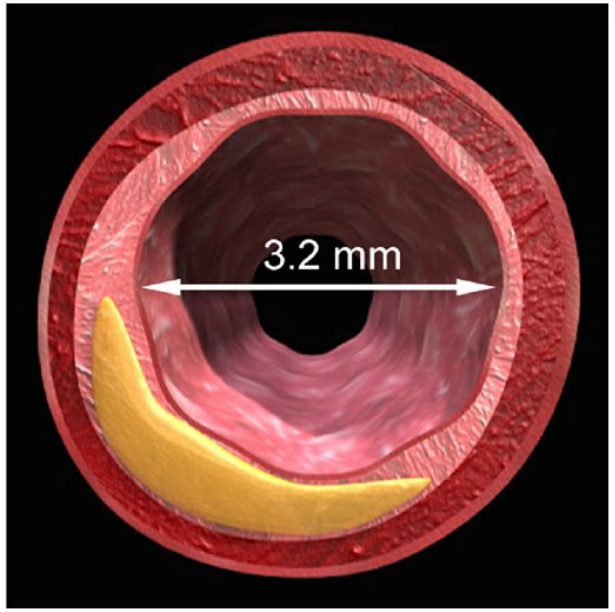

IVUS Measurements of Atheroma Volume

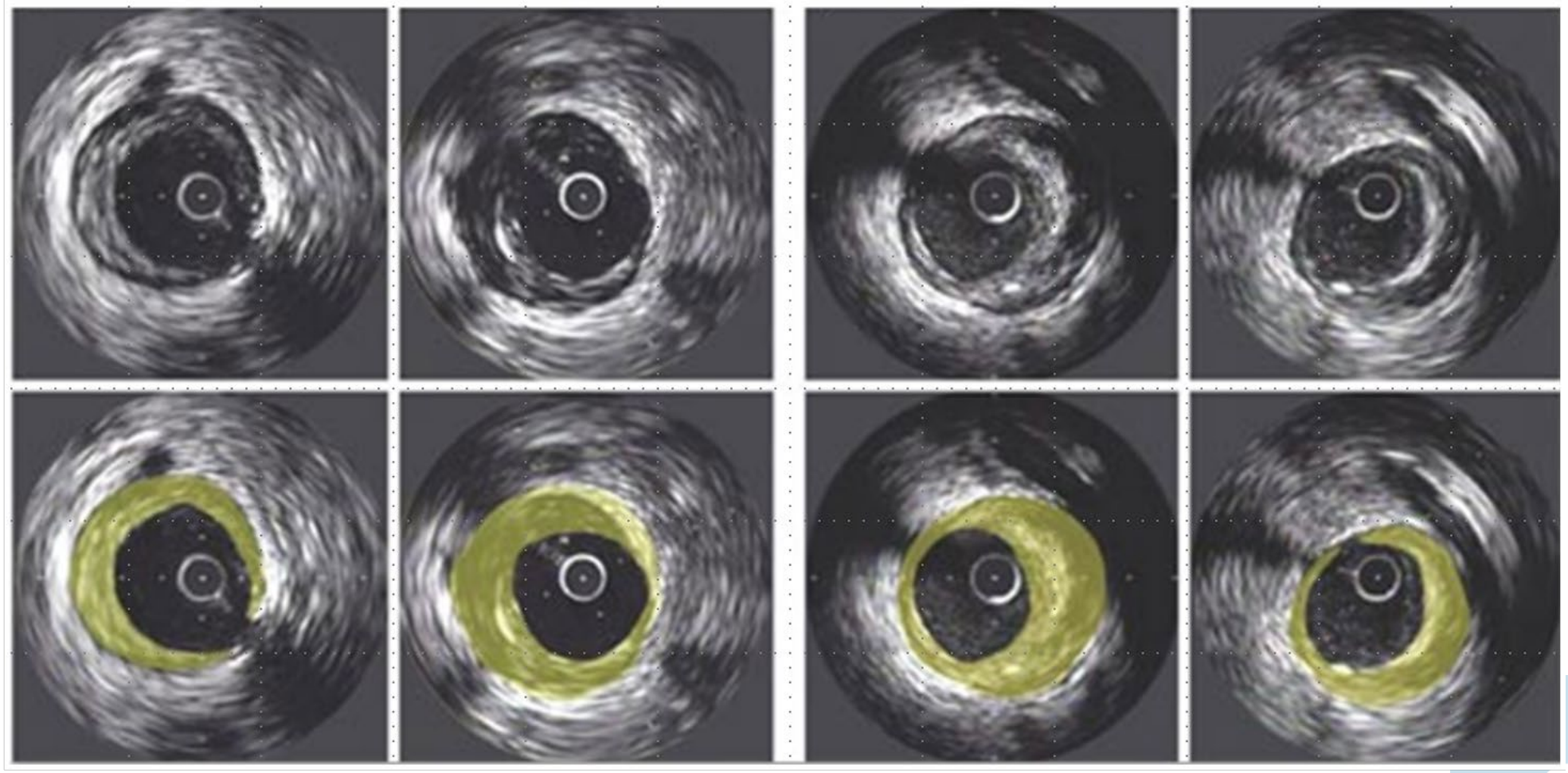

PROGRESSION

REGRESSION

Puri R. et al. Int J Cardiol 2013

What Have We Learned From Serial IVUS Trials

BENEFICIAL IMPACT

High-intensity statin therapy

Blood pressure lowering

Pioglitazone in diabetes

Evolocumab

NO BENEFIT

ACAT inhibition

Torcetrapib, ?CETP inhibition

Rimonabant

Lp-PLA2_2 Inhibition

ApoA-1 Milano

RVX 208

CER-001

Intravascular Ultrasound: Principles

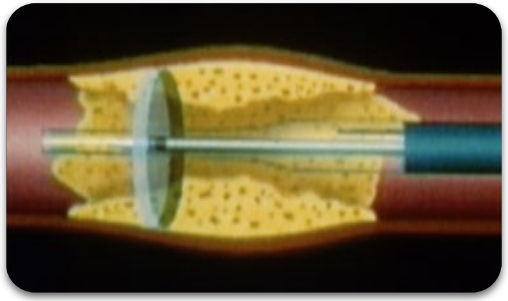

IVUS transducer rotates and pulls back through an area of interest and emits sound waves. Multiple pullback speeds are available.

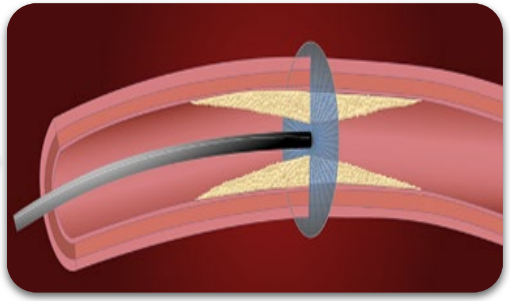

Sound waves are reflected or pass through structures dependent on their density or acoustic impedance.

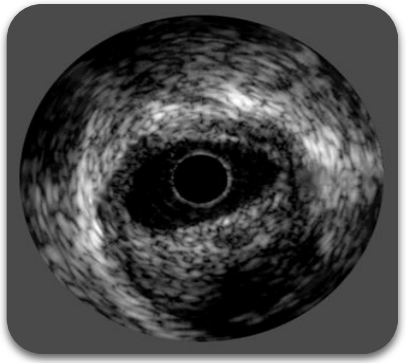

The electrical pulses are analyzed and processed by a complex computerized imaging system and displayed on a screen.

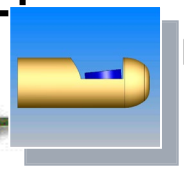

Rotating Element

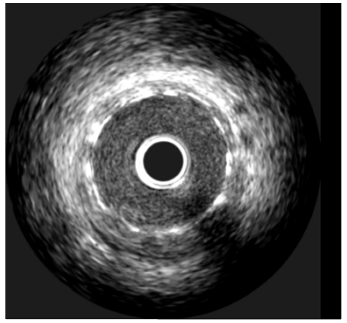

Higher resolution

Mechanical Transducer (40-60 MHz)

- Single transducer rotates on a drive shaft, 1800 rpm

Synthetic Phased Array / Solid State Transducer (20 MHz)

- Multiple (64) stationary transducers

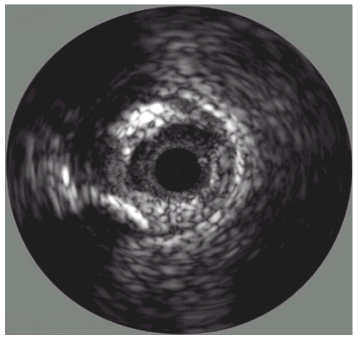

Lower resolution

Recent more recent developments in conventional rotational IVUS

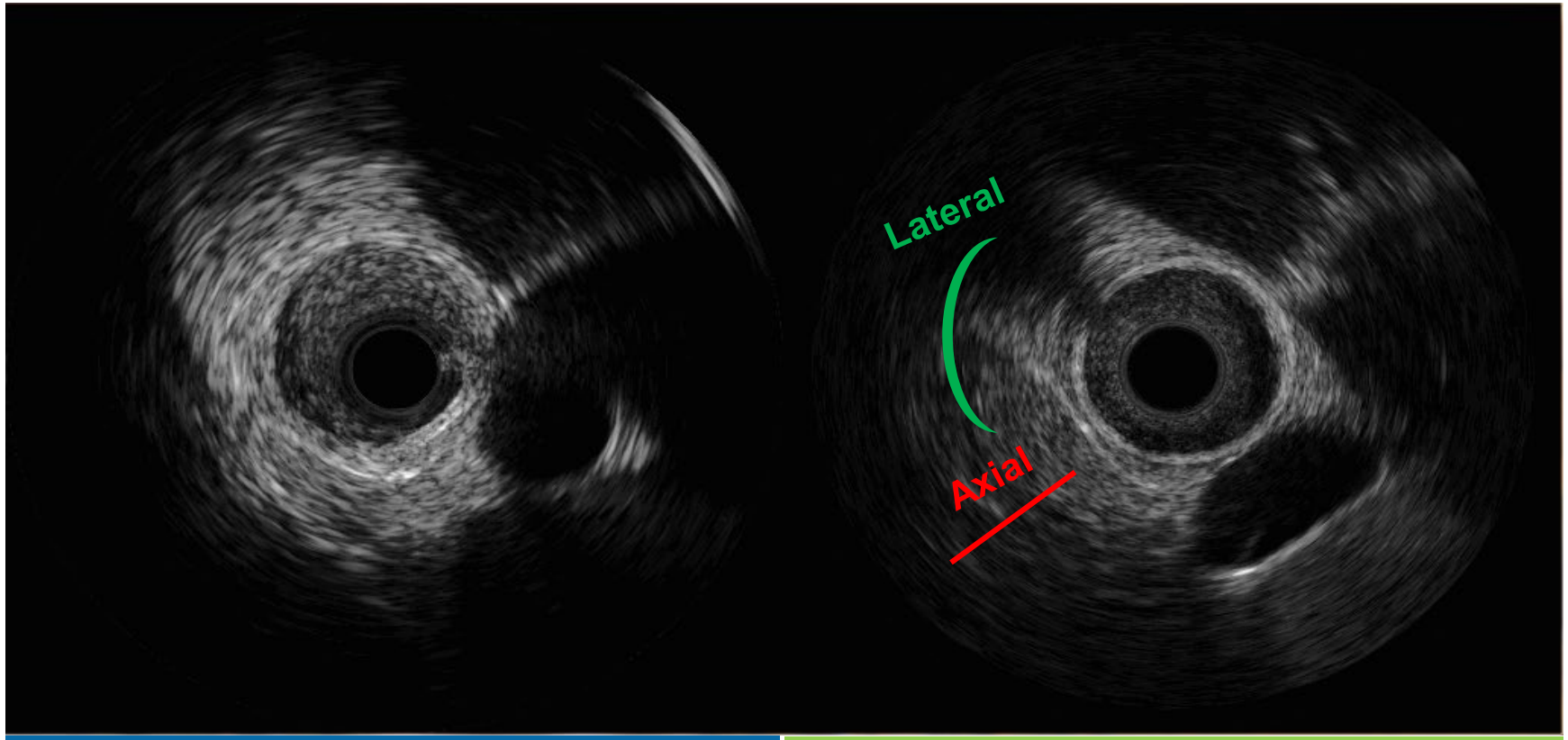

OPTICROSS™ Imaging Catheter 40 MHz	OPTICROSS™ HD Imaging Catheter 60 MHz

IVUS Image Interpretation

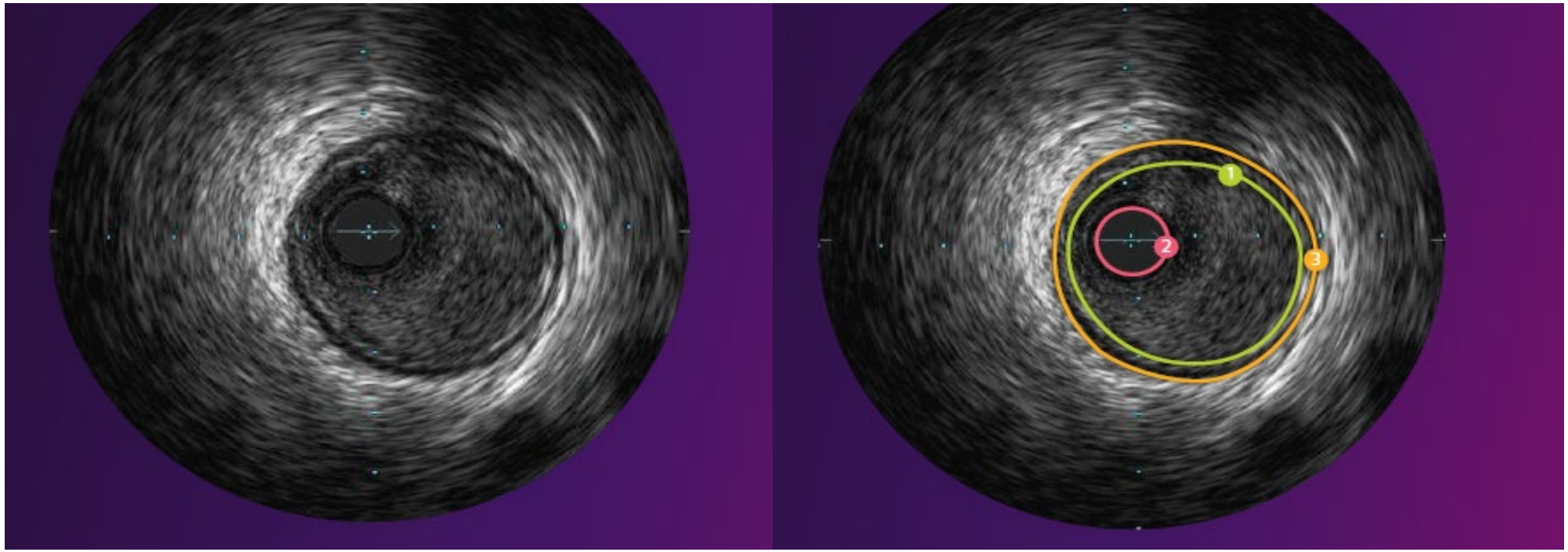

Normal vessel

- Pink is IVUS catheter
  - Green is lumen
  - Orange is EEM
- Dark band = media

IVUS Image Interpretation

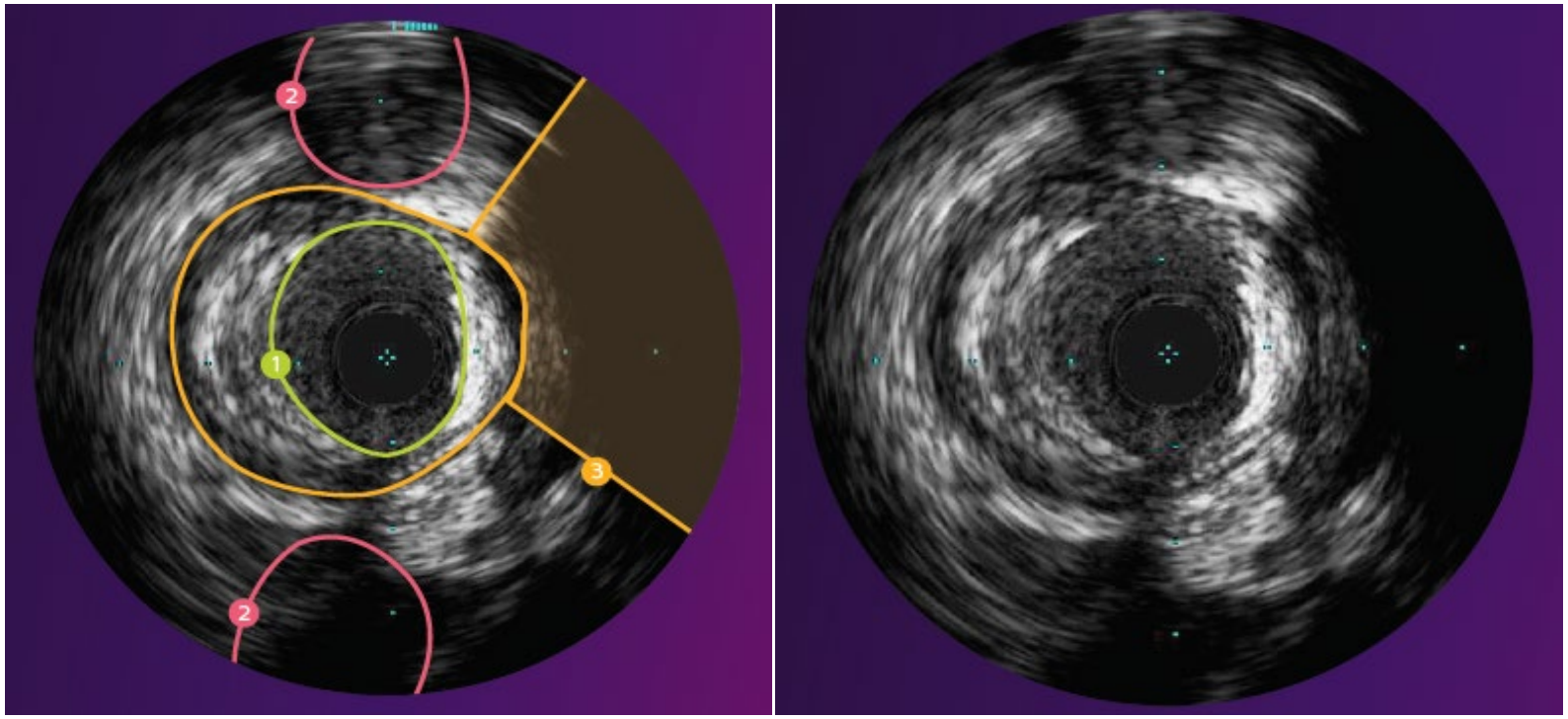

Eccentric mixed plaque

- Pink are sidebranches
- Green is lumen
- Orange is acoustic shadowing (Ca)

IVUS Image Interpretation

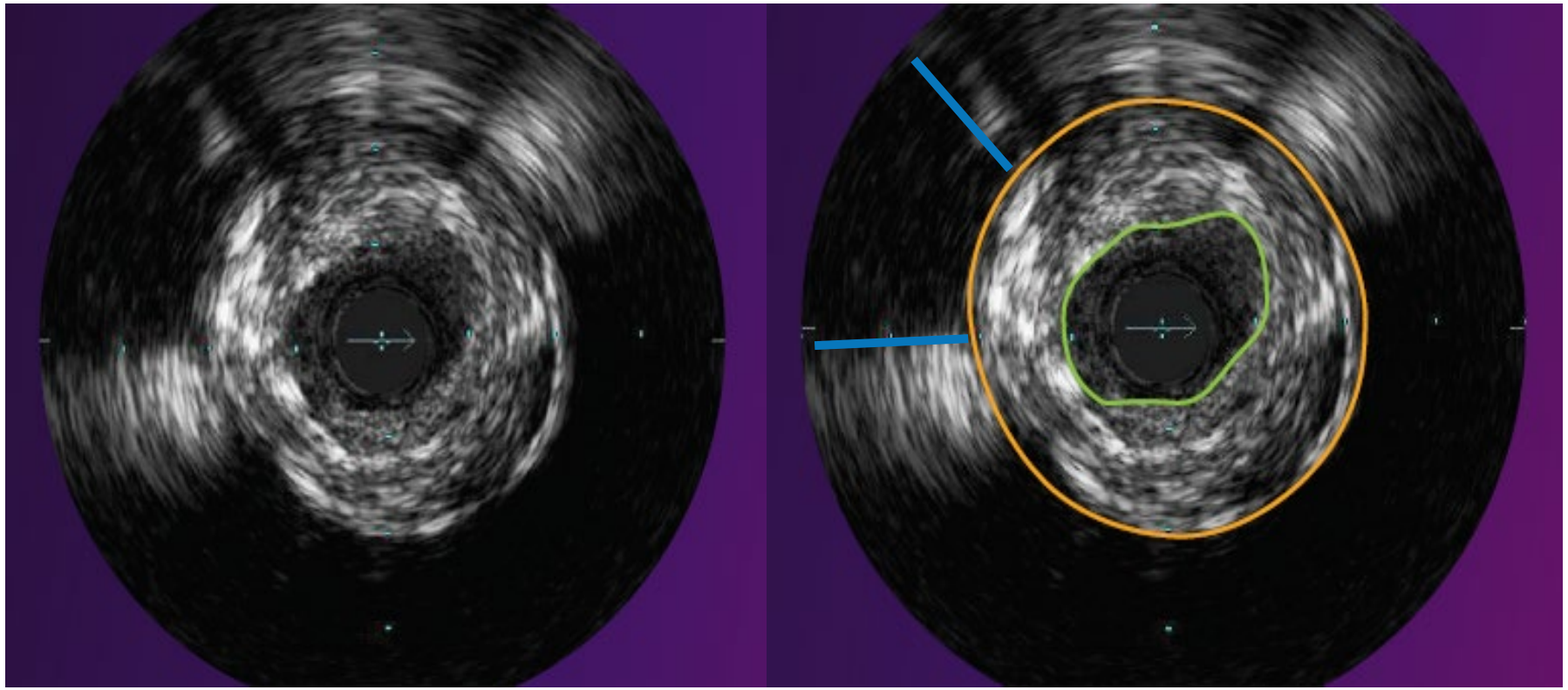

Concentric mixed plaque

- Circumferential plaque distribution
  - Varying echogenicity
    - Fibrocalcific
- Acoustic shadow (blue lines)

IVUS Image Interpretation

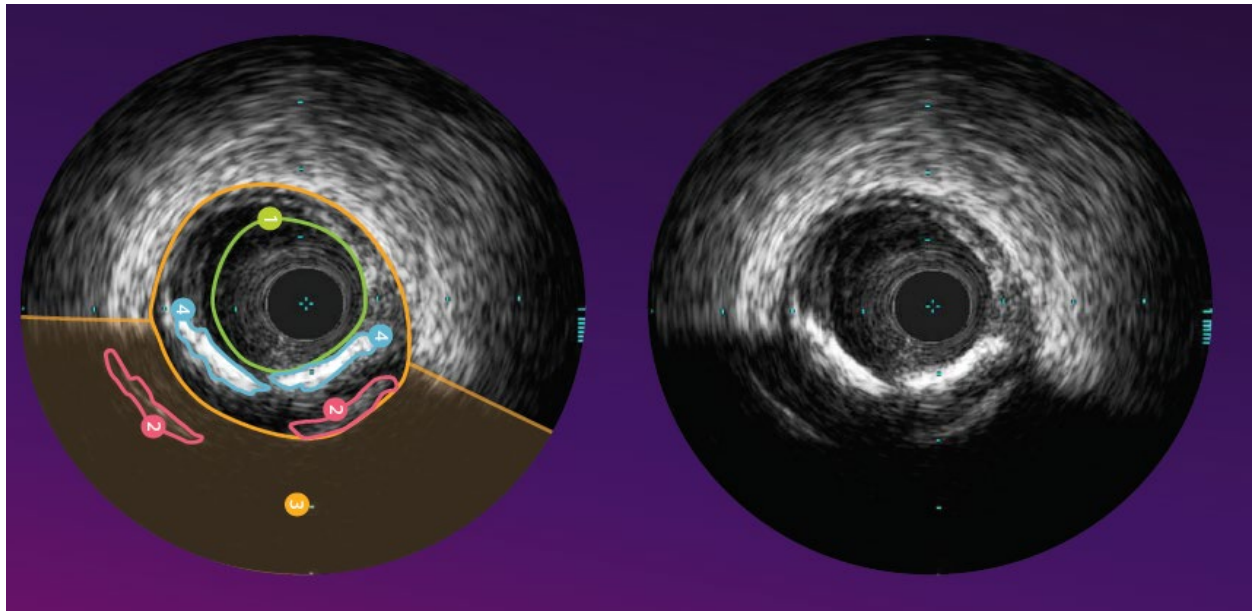

Calcified plaque

- Bright areas (blue) with acoustic shadowing (orange)
- Reverberation artifact (pink)

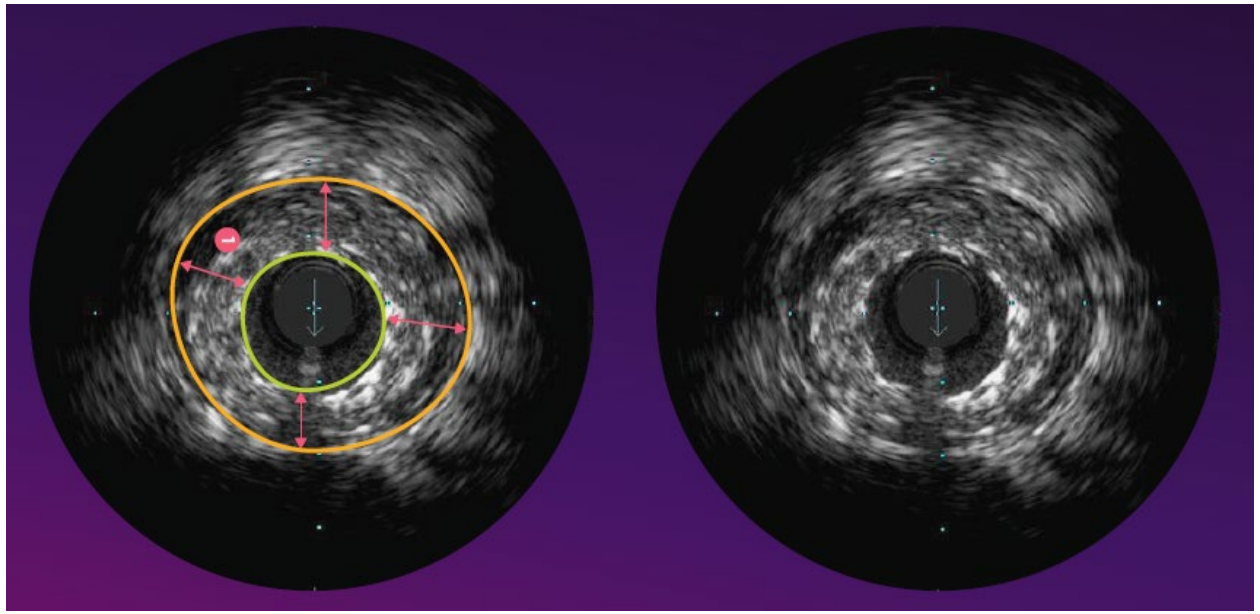

Underexpanded stent

- Stent struts are bright
- Significant plaque burden behind stent (pink arrow)

IVUS Image Interpretation

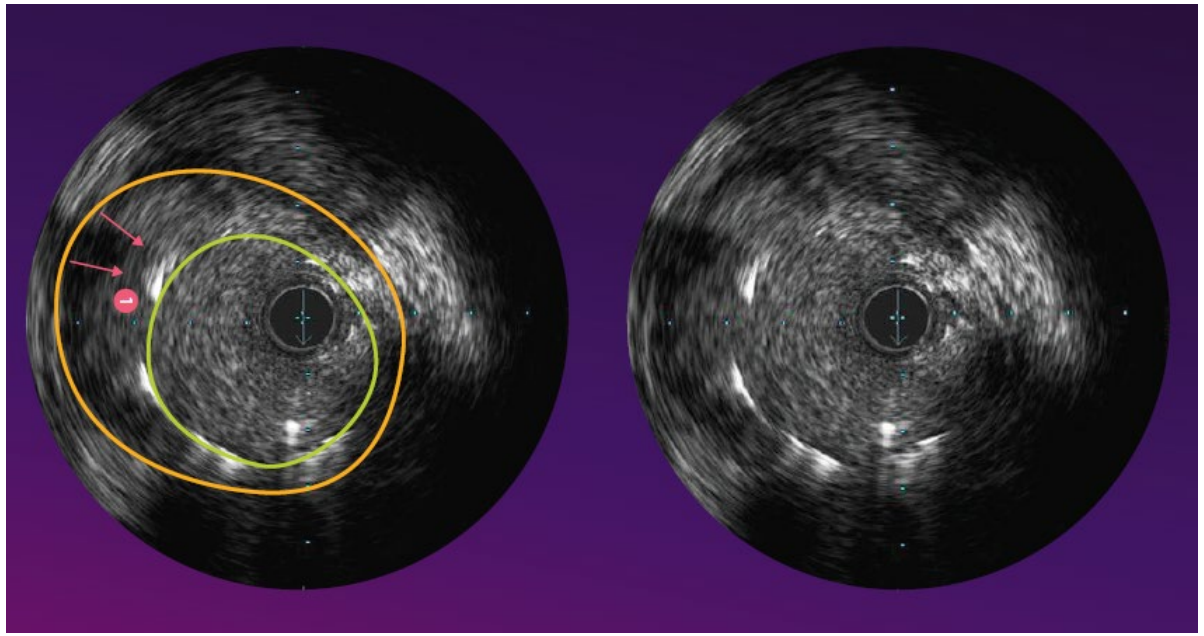

Malapposed stent

- Blood speckle behind stent struts
  - Area of malapposition (pink)

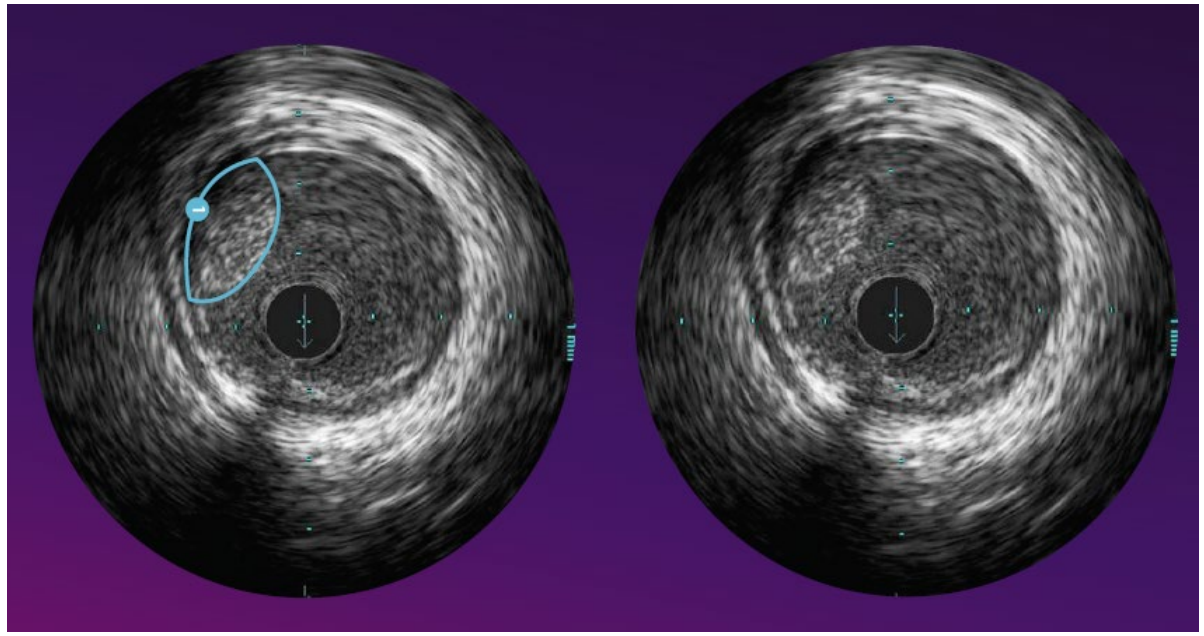

Intraluminal thrombus

- Usually circular and non-stationary
- Can inject contrast to highlight contours

IVUS Image Interpretation

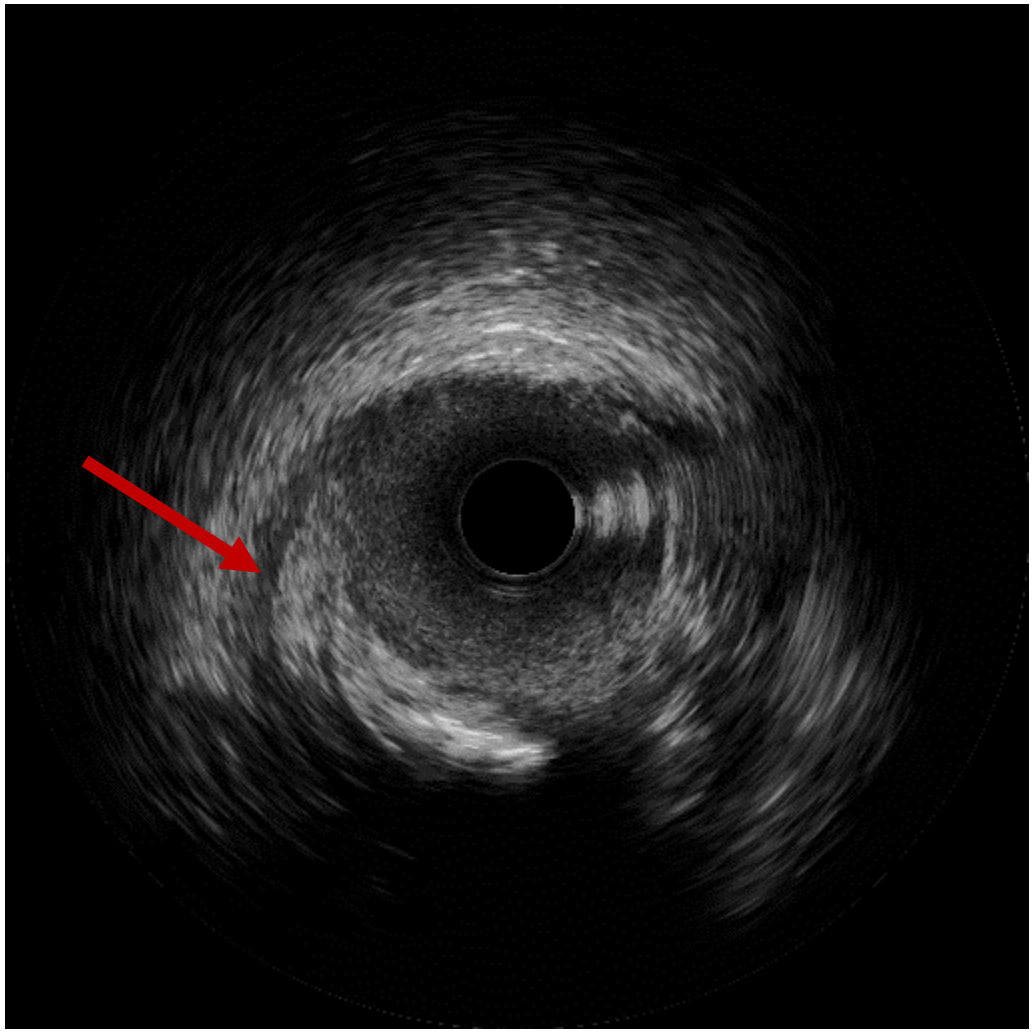

Dissection

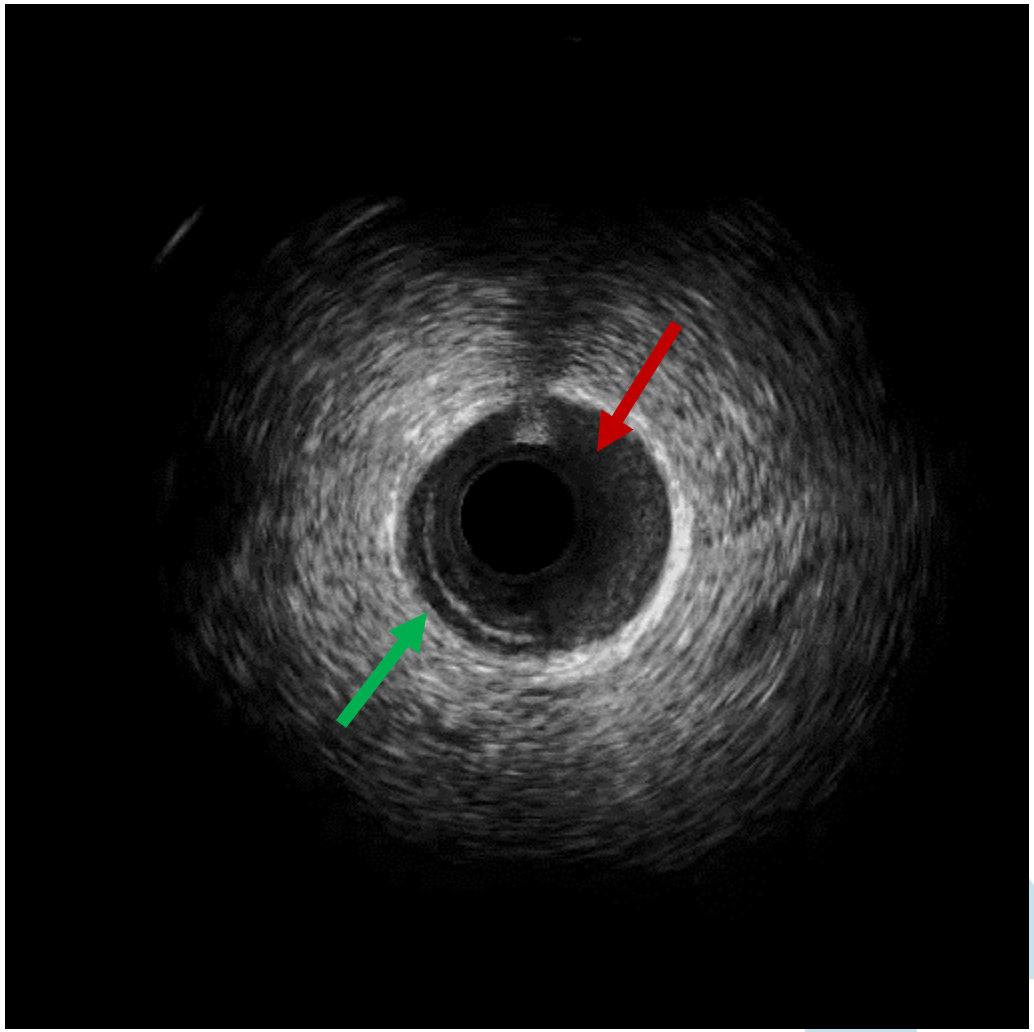

False lumen

IVUS Image Interpretation

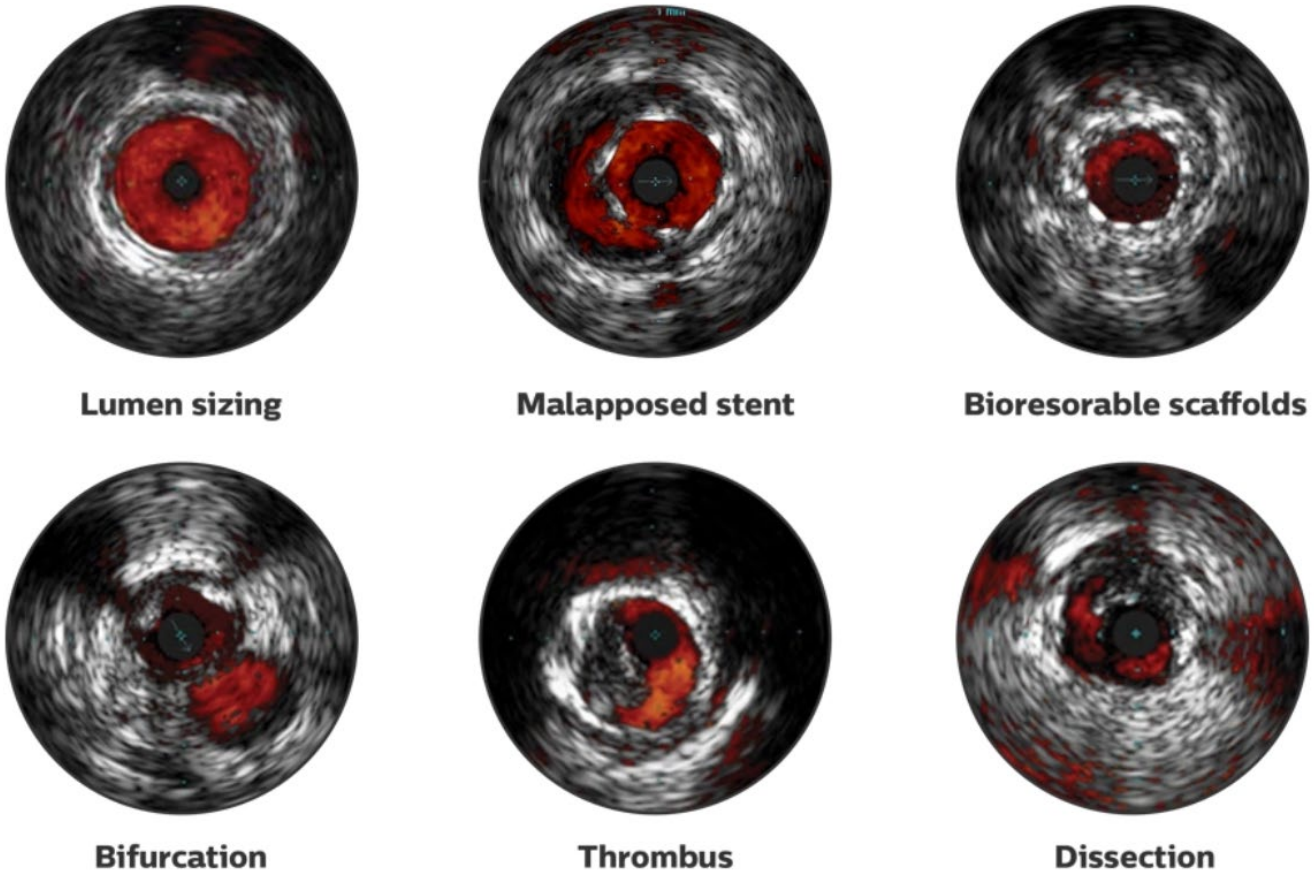

IVUS Chromaflo

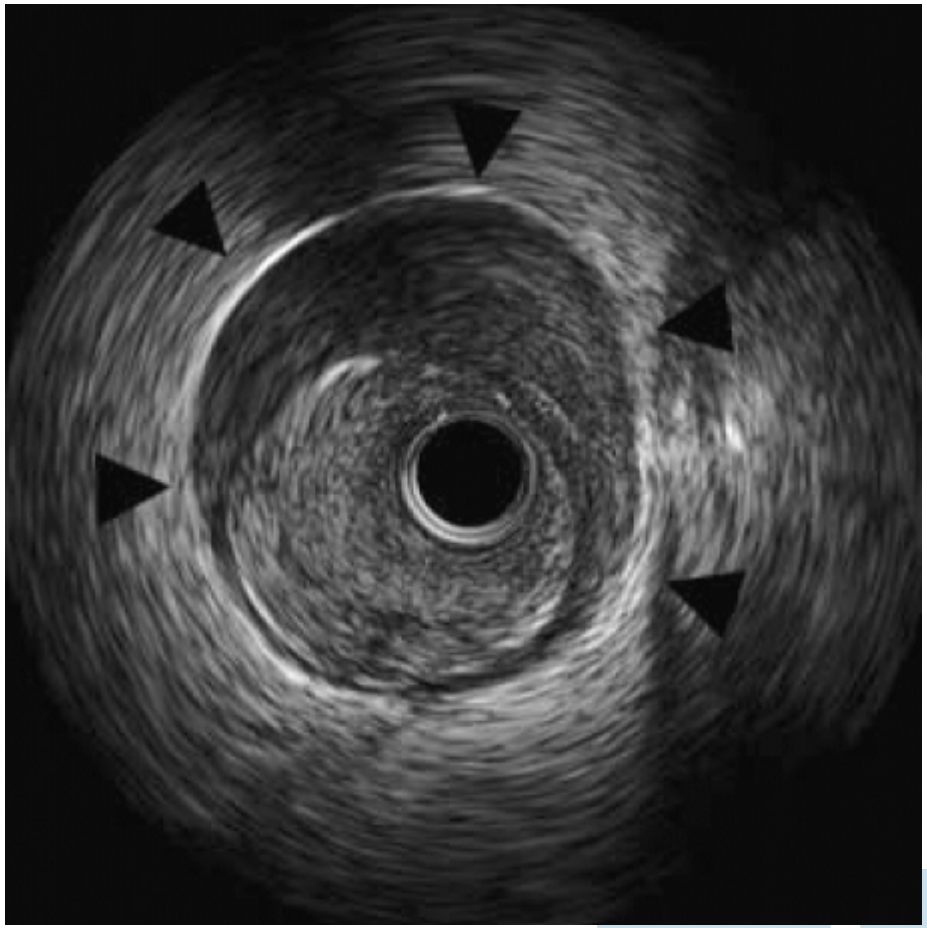

Hematoma

Optical Coherence Tomography: Principles

Analogous to IVUS, but uses NIR light instead of sound to measure optical reflections

High-resolution imaging technology employing NIR light to probe micrometer-scale structures inside biological tissues

1300 nm wavelength light

Dragon Fly catheter

2.7 Fr

75 mm pullback/2.5 secs

Clear lumen with contrast

10-20 micron axial resolution

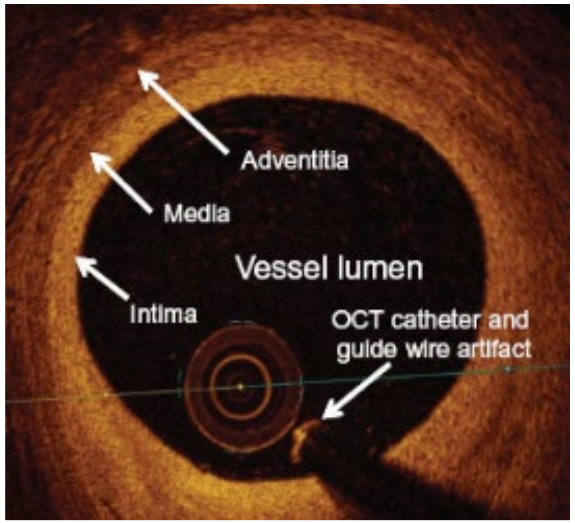

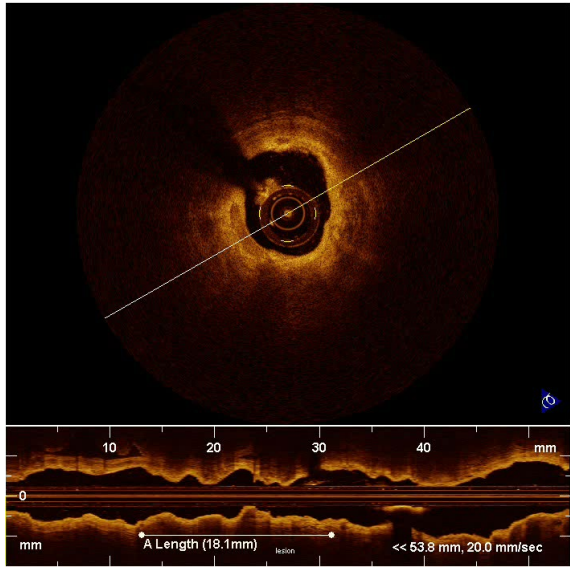

OCT Image Interpretation: Plaque, Device & Complications

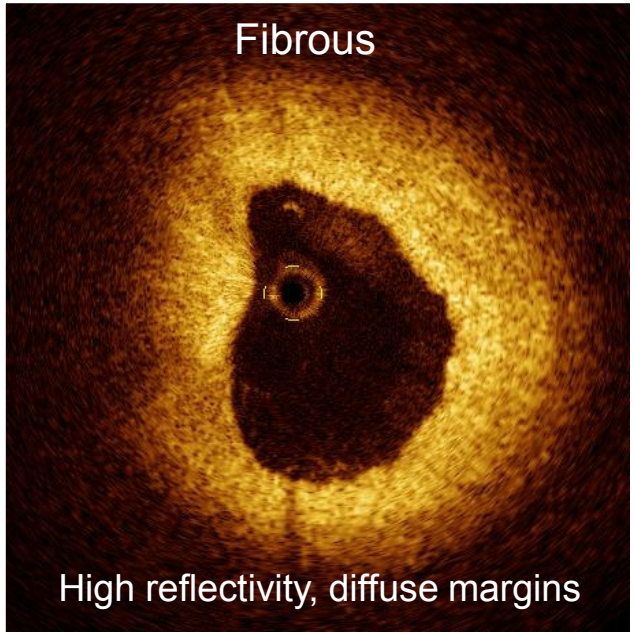

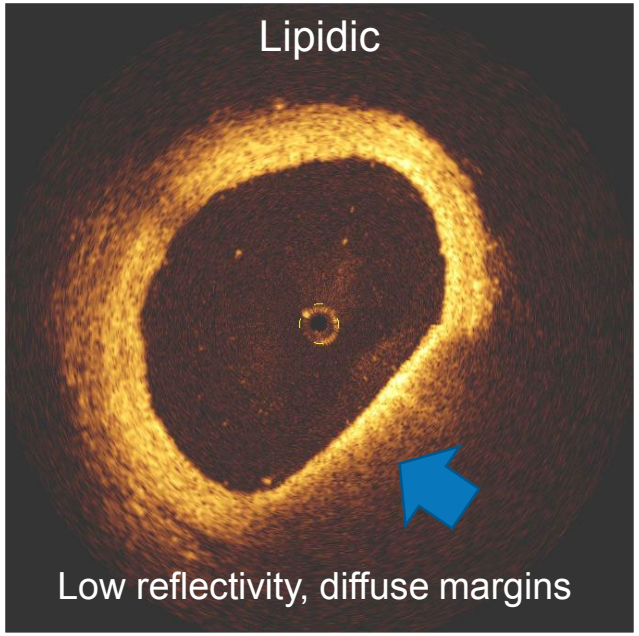

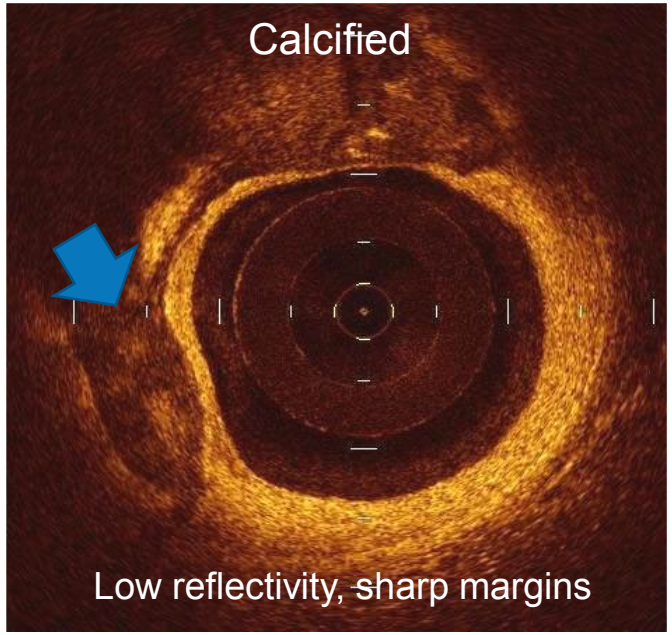

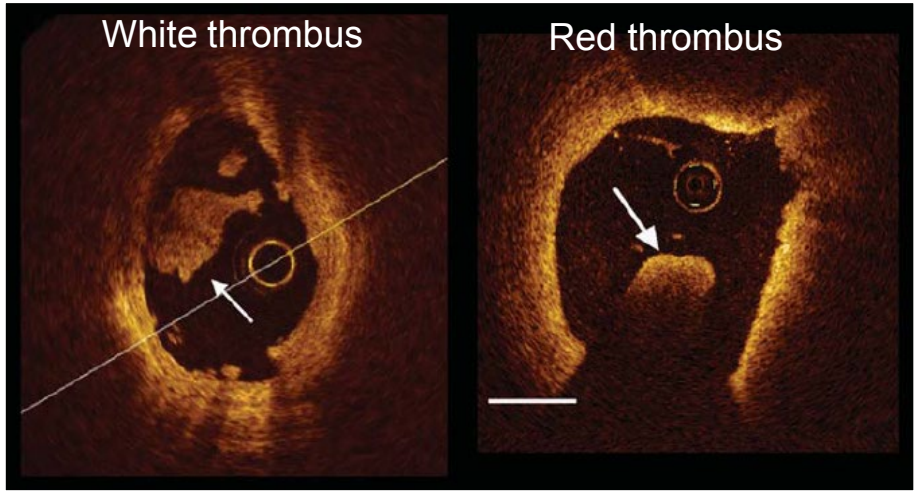

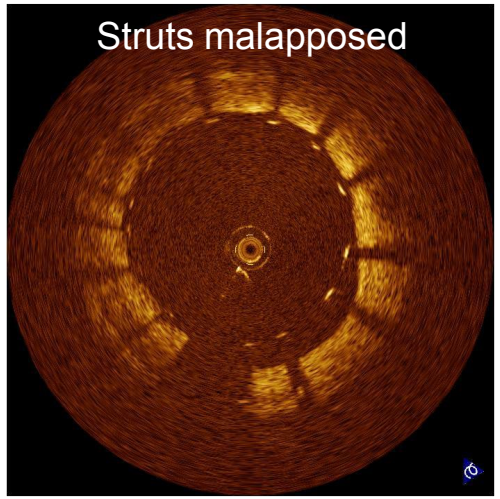

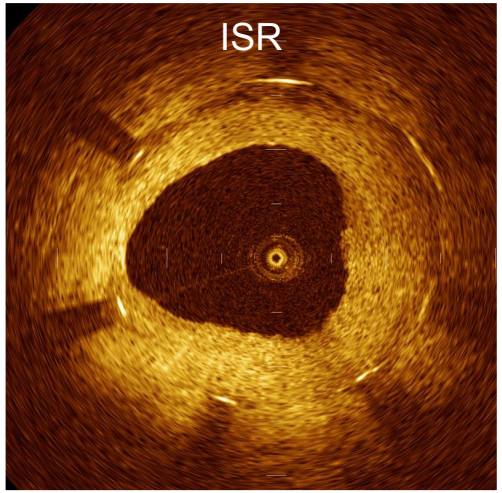

IVUS and OCT Image Interpretation

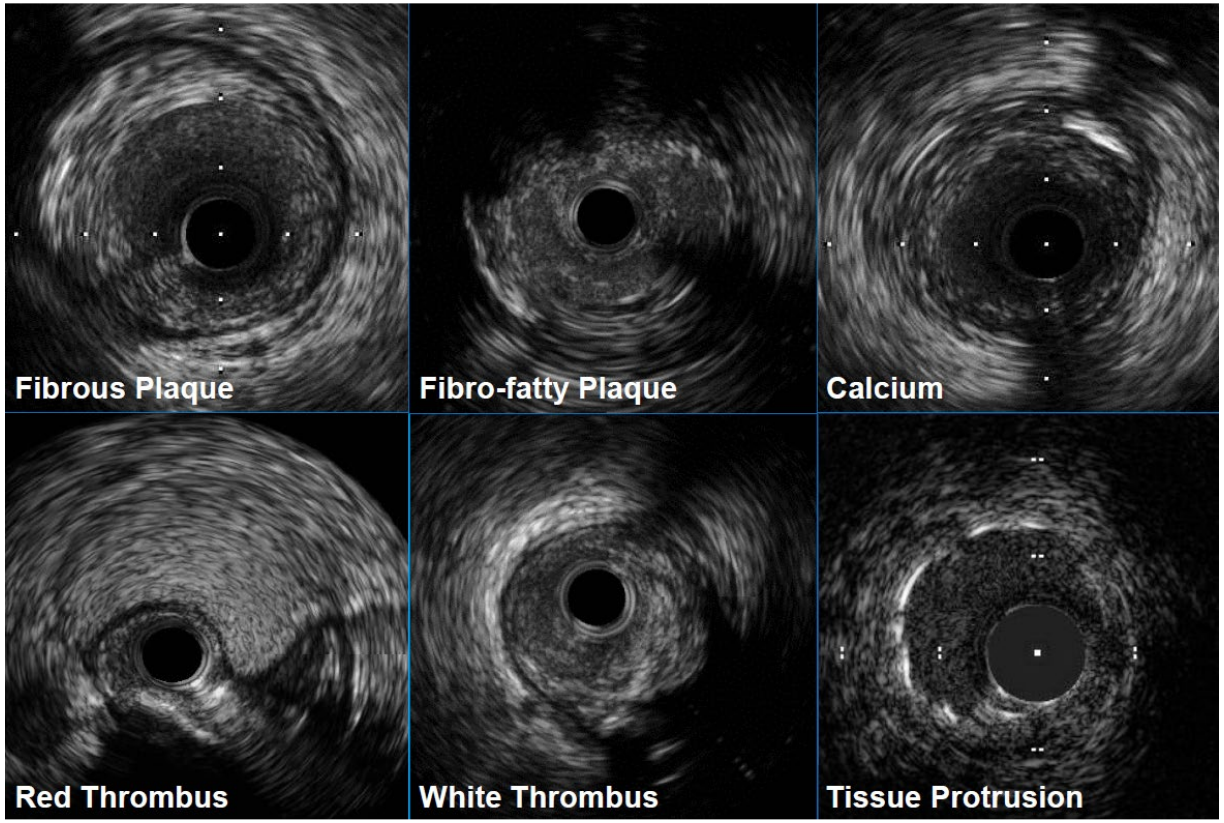

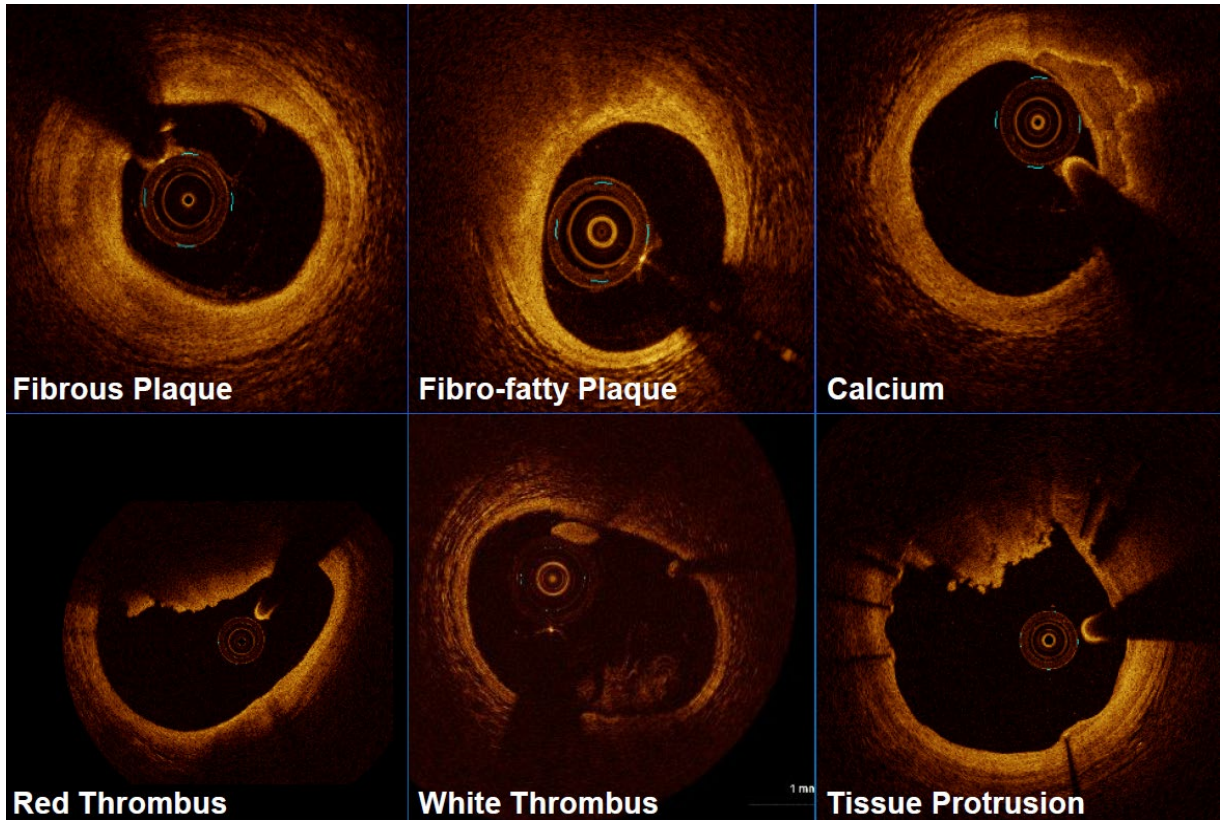

TRAIN YOUR EYES!

Slightly larger stent diameters with IVUS

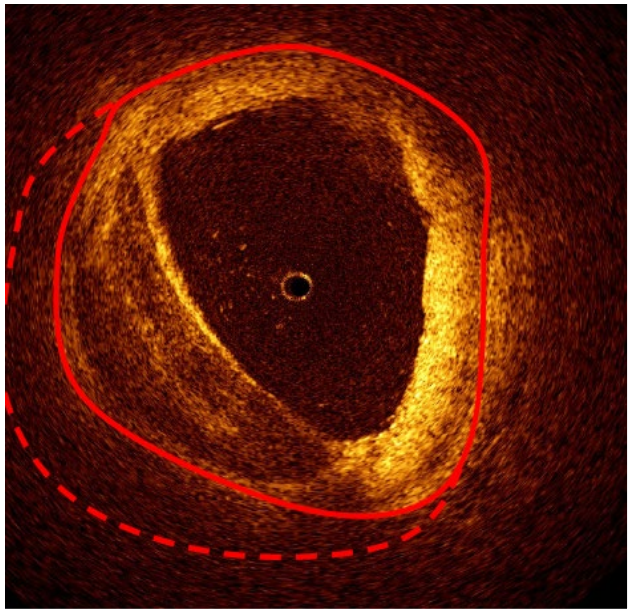

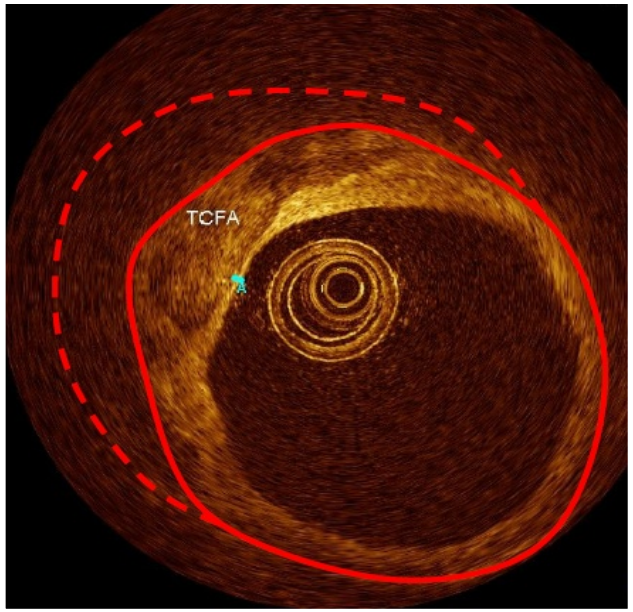

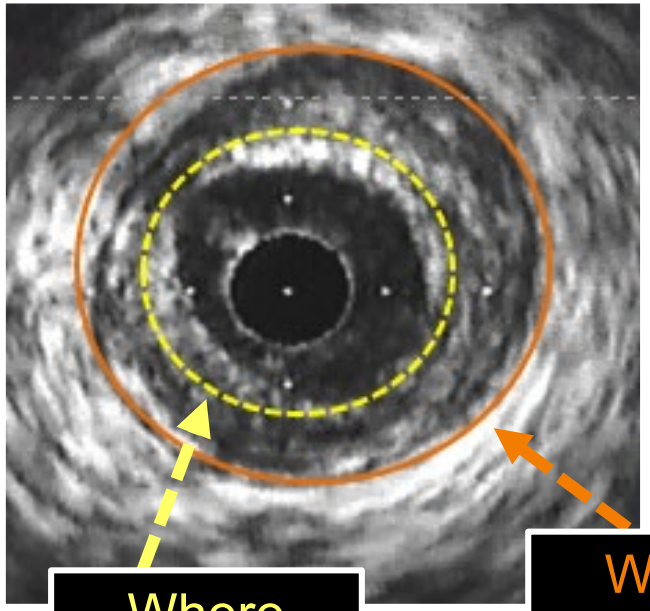

Where OCT images to

Where IVUS images to

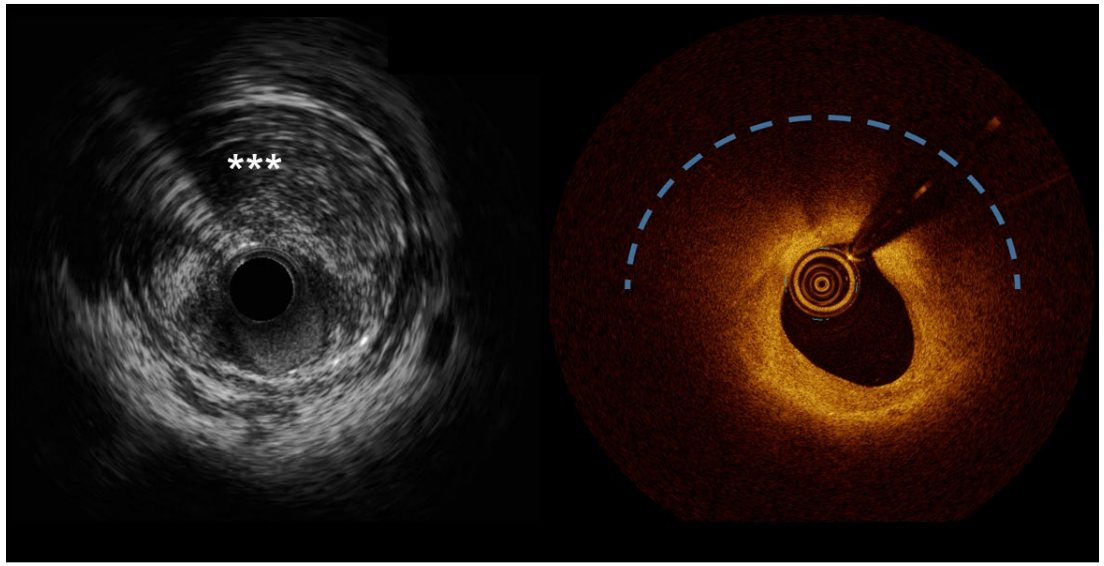

WHAT IS THE VESSEL SIZE ??

IVUS vs. OCT

CENTRAL ILLUSTRATION: IVUS and OCT: Similarities and Differences

OCT: Very good	OCT: Good	OCT: Feasible		IVUS: Feasible	IVUS: Good	IVUS: Very good
			Pre-PCI			
●	●	●	Severity of calcium	●	●	
		●	Prediction of slow flow	●		
	●	●	Stent sizing by vessel wall	●	●	●
●	●	●	Stent length to cover normal to normal	●	●	●
			Post-PCI			
●	●	●	Stent expansion	●	●	●
●	●	●	Tissue protrusion through strut	●	●	
●	●	●	Stent malapposition	●	●	
	●	●	Stent deformation (frequently at aorto-ostium)	●	●	
●	●	●	Stent edge dissection	●	●	
●	●	●	Residual disease at stent edge	●	●	●
			Follow-up			
●	●	●	Old stent expansion	●	●	●
	●	●	Tissue coverage	●		
●	●	●	Neointimal hyperplasia	●	●	●
	●	●	Stent fracture	●	●	
●	●	●	Stent malapposition	●	●	
		●	Positive remodeling of vessel wall	●	●	●
●	●	●	Neoatherosclerosis	●	●	

	IVUS	OCT
Severe Calcification	+	+++
CTO	+++	+
LMCA	+++	+
Ostial Disease	+++	+
Advanced CKD	+++	+

Maehara A et al. JACC CV Img 2017

Intravascular Imaging Improving Stent/Patient Outcomes

Randomized Trials

1) Jakabcin J, Spacek R, Bystron M, et al. Long-term health outcome and mortality evaluation after invasive coronary treatment using drug eluting stents with or without the IVUS guidance. Randomized control trial. HOME DES IVUS. Catheter Cardiovasc Interv 2010;75:578-583.
2) Chieffo A, Latib A, Caussin C, et al. A prospective, randomized trial of intravascular-ultrasound guided compared to angiography guided stent implantation in complex coronary lesions: the AVIO trial. Am Heart J 2013;165:65-72.
3) Kim JS, Kang TS, Mintz GS, et al. Randomized comparison of clinical outcomes between intravascular ultrasound and angiography-guided drug-eluting stent implantation for long coronary artery stenoses. JACC Cardiovasc Interv 2013;6:369-376.
4) Hong SJ, Kim BK, Shin DH, et al; IVUS-XPL Investigators. Effect of intravascular ultrasound-guided vs angiography-guided everolimus-eluting stent implantation: the IVUS-XPL randomized clinical trial. JAMA 2015;314:2155-63.
5) Tian NL, Gami SK, Ye F, et al. Angiographic and clinical comparisons of intravascular ultrasound- versus angiography-guided drug-eluting stent implantation for patients with chronic total occlusion lesions: two-year results from a randomised AIR-CTO study. EuroIntervention 2015;10:1409-17.
6) Kim BK, Shin DH, Hong MK, et al; CTO-IVUS Study Investigators. Clinical impact of intravascular ultrasound-guided chronic total occlusion intervention with zotarolimus-eluting versus biolimus-eluting stent implantation: randomized study. Circ Cardiovasc Interv 2015;8, e002592.
7) Tan Q, Wang Q, Liu D, et al. Intravascular ultrasound–guided unprotected left main coronary artery stenting in the elderly. Saudi Med J 2015;36:549-53.
8) Zhang JQ, Shi R, Pang W, et al. Application of intravascular ultrasound in stent implantation for small coronary arteries. J Clin Invasive Cardiol 2016;3:1-8.
9) Mariani J Jr, Guedes C, Soares P, et al. Intravascular ultrasound guidance to minimize the use of iodine contrast in percutaneous coronary intervention: the MOZART (Minimizing cOntrast utilizZation With IVUS Guidance in coRonary angioplasTy) randomized controlled trial. JACC Cardiovasc Interv. 2014;7:1287-93
10) Habara M, Nasu K, Terashima M, et al. Impact of frequency-domain optical coherence tomography guidance for optimal coronary stent implantation in comparison with intravascular ultrasound guidence. Circ Cardiovasc Interv. 2012;5:193-201
11) Ali ZA, Maehara A, Généreux P, et al. Optical coherence tomography compared with intravascular ultrasound and with angiography to guide coronary stent implantation (ILUMIEN III: OPTIMIZE PCI): a randomised controlled trial. Lancet. 2016;388:2618-28
12) Meneveau N, Souteyrand G, Motreff P, et al. Optical Coherence Tomography to Optimize Results of Percutaneous Coronary Intervention in Patients with Non-ST-Elevation Acute Coronary Syndrome: Results of the Multicenter, Randomized DOCTORS Study (Does Optical Coherence Tomography Optimize Results of Stenting). Circulation. 2016;134:906-17
13) Kubo T, Shinke T, Okamura T, et al. Optical frequency domain imaging vs. intravascular ultrasound in percutaneous coronary intervention (OPINION trial): one-year angiographic and clinical results. Eur Heart J. 2017;38:3139-47.
14) Kala P, Cervinka P, Jakl M, et al. OCT guidance during stent implantation in primary PCI: A randomized multicenter study with nine months of optical coherence tomography follow-up. Int J Cardiol. 2018;250:98-103

Meta-analyses

1) Zhang Y, Farooq V, Garcia-Garcia HM, et al. Comparison of intravascular ultrasound versus angiography-guided drug-eluting stent implantation: a meta-analysis of one randomised trial and ten observational studies involving 19,619 patients. EuroIntervention. 2012;8:855-65.
2) Klersy C, Ferlini M, Raisaro A, et al. Use of IVUS guided coronary stenting with drug eluting stent: a systematic review and meta-analysis of randomized controlled clinical trials and high quality observational studies. Int J Cardiol. 2013;170:54-63.
3) Jang JS, Song YJ, Kang W, et al. Intravascular ultrasound-guided implantation of drug-eluting stents to improve outcome: a meta-analysis. JACC Cardiovasc Interv. 2014;7:233-43.
4) Ahn JM, Kang SJ, Yoon SH, et al. Meta-analysis of outcomes after intravascular ultrasound-guided versus angiography-guided drug-eluting stent implantation in 26,503 patients enrolled in three randomized trials and 14 observational studies. Am J Cardiol. 2014;113:1338-47
5) Zhang YJ, Pang S, Chen XY, et al. Comparison of intravascular ultrasound guided versus angiography guided drug eluting stent implantation: a systematic review and meta-analysis. BMC Cardiovasc Disord. 2015;15:153.
6) Alsidawi S, Effat M, Rahman S, Abdallah M, Leesar M. The role of vascular imaging in guiding routine percutaneous coronary interventions: A meta-analysis of bare Metal stent and drug-eluting stent trials. Cardiovasc Ther. 2015;33:360-6.
7) Nerlekar N, Cheshire CJ, Verma KP, et al. Intravascular ultrasound guidance improves clinical outcomes during implantation of both first and second-generation drug-eluting stents: a meta-analysis. EuroIntervention 2017;12:1632-42.
8) Steinvil A, Zhang YJ, Lee SY, et al. Intravascular ultrasound-guided drug-eluting stent implantation: An updated meta-analysis of randomized control trials and observational studies. Int J Cardiol. 2016;216:133-9.
9) Elgendy IY, Mahmoud AN, Elgendy AY, et al. Outcomes with intravascular ultrasound-guided stent implantation: A meta-analysis of randomized trials in the era of drug-eluting stents. Circ Cardiovasc Interv. 2016;9:e003700.
10) Shin DH, Hong SJ, Mintz GS, et al. Effects of intravascular ultrasound-guided versus angiography-guided new-generation drug-eluting stent implantation: Meta-Analysis With Individual Patient-Level Data From 2,345 Randomized Patients. JACC Cardiovasc Interv. 2016;9:2232-9.
11) Bavishi C, Sardar P, Chatterjee S, et al. Intravascular ultrasound–guided vs angiography-guided drug-eluting stent implantation in complex coronary lesions: Meta-analysis of randomized trials. Am Heart J. 2017 Mar;185:26-34.
12) Fan ZG, Gao XF, Li XB, Shao MX, Gao YL, Chen SL, Tian NL. The outcomes of intravascular ultrasound-guided drug-eluting stent implantation among patients with complex coronary lesions: a comprehensive meta-analysis of 15 clinical trials and 8,084 patients. Anatol J Cardiol. 2017;17:258-68
13) Ye Y, Yang M, Zhang S, Zeng Y. Percutaneous coronary intervention in left main coronary artery disease with or without intravascular ultrasound: A meta-analysis. PLoS One. 2017 Jun 22;12(6):e0179756.
14) Buccheri S, Franchina G, Romano S, Puglisi S, Venuti G, D'Arrigo P, Francaviglia B, Scalia M, Condorelli A, Barbanti M, Caprazonzo P, Tamburino C, Capodanno D. Clinical outcmoes following intravascular imaging-guided versus coronary angiography guided percutaneous coronary intervention with stent implantation. A systematic review and Bayesian network meta-analysis of 31 studies and 17,882 patients. JACC Cardiovasc Interv 2017;10:2488-98.
15) Kuku KO, Ekanem E, Azizi V, et al. Optical coherence tomography-guided percutaneous coronary intervention compared with other imaging guidance: a meta-analysis. Int J Cardiovasc Imaging. 2018;34:503-13

Registries

1) Agostoni P, Valgimigli M, Van Mieghem CA, et al. Comparison of early outcome of percutaneous coronary intervention for unprotected left main coronary artery disease in the drug-eluting stent era with versus without intravascular ultrasonic guidance. Am J Cardiol 2005;95:644-647.
2) Roy P, Steinberg DH, Sushinsky SJ, et al. The potential clinical utility of intravascular ultrasound guidance in patients undergoing percutaneous coronary intervention with drug-eluting stents. Eur Heart J 2008;29:1851-7.
3) Fujimoto H, Tao S, Dohi T, et al. Primary and mid-term outcome of sirolimus-eluting stent implantation with angiographic guidance alone. J Cardiol. 2008;51:18-24 .
4) Park SJ, Kim YH, Park DW, et al; Investigators M-C. Impact of intravascular ultrasound guidance on long-term mortality in stenting for unprotected left main coronary artery stenosis. Circ Cardiovasc Interv 2009;2:167-177.
5) Kim SH, Kim YH, Kang SJ et al. Long-term outcomes of intravascular ultrasound-guided stenting in coronary bifurcation lesions. Am J Cardiol 2010;106:612-618.
6) Maluenda G, Lemesle G, Ben-Dor I, et al. Impact of intravascular ultrasound guidance in patients with acute myocardial infarction undergoing percutaneous coronary intervention. Catheter Cardiovasc Interv 2010;75:86-92.
7) Claessen BE, Mehran R, Mintz GS, et al. Impact of intravascular ultrasound imaging on early and late clinical outcomes following percutaneous coronary intervention with drug-eluting stents. JACC Cardiovasc Interv 2011;4:974-981.
8) Kim JS, Hong MK, Ko YG, et al. Impact of intravascular ultrasound guidance on long-term clinical outcomes in patients treated with drug-eluting stent for bifurcation lesions: data from a Korean multicenter bifurcation registry. Am Heart J 2011;161:180-187.
9) Youn YJ, Yoon J, Lee JW, et al. Intravascular ultrasound-guided primary percutaneous coronary intervention with drug-eluting stent implantation in patients with ST-segment elevation myocardial infarction. Clin Cardiol 2011;34:706-713.
10) Chen SL, Ye F, Zhang JJ, et al. Intravascular ultrasound-guided systematic two-stent techniques for coronary bifurcation lesions and reduced late stent thrombosis. Catheter Cardiovasc Interv 2013;81:456-463.
11) Hur SH, Kang SJ, Kim YH, et al. Impact of intravascular ultrasound-guided percutaneous coronary intervention on long-term clinical outcomes in a real world population. Catheter Cardiovasc Interv 2013;81:407-416.
12) Park KW, Kang SH, Yang HM, et al. Impact of intravascular ultrasound guidance in routine percutaneous coronary intervention for conventional lesions: data from the EXCELLENT trial. Int J Cardiol 2013;167:721-726.
13) Witzenbichler B, Maehara A, Weisz G, et al. Relationship between intravascular ultrasound guidance and clinical outcomes after drug-eluting stents: The ADAPT-DES Study. Circulation. 2014;129:463-70
14) Ahn SG, Yoon J, Sung JK, et al. Intravascular ultrasound-guided percutaneous coronary intervention improves the clinical outcome in patients undergoing multiple overlapping drug-eluting stents implantation. Korean Circ J 2013;43:231-8.
15) Ahn JM, Han S, Park YK, et al; RESET Investigators. Differential prognostic effect of intravascular ultrasound use according to implanted stent length. Am J Cardiol 2013;111:829-835.
16) Yoon YW, Shin S, Kim BK, et al; Investigators R. Usefulness of intravascular ultrasound to predict outcomes in short-length lesions treated with drug-eluting stents. Am J Cardiol 2013;112:642-646.
17) de la Torre Hernandez JM, Baz Alonso JA, Gómez Hospital JA, et al; IVUS-TRONCO-ICP Spanish study. Clinical impact of intravascular ultrasound guidance in drug-eluting stent implantation for unprotected left main coronary disease: pooled analysis at the patient-level of 4 registries. JACC Cardiovasc Interv. 2014;7:244–54.
18) Hong SJ, Kim BK, Shin DH, et al; K-CTO Registry. Usefulness of intravascular ultrasound guidance in percutaneous coronary intervention with second-generation drug-eluting stents for chronic total occlusions (from the Multicenter Korean-Chronic Total Occlusion Registry). Am J Cardiol. 2014;114:534–40.
19) Gao XF, Kan J, Zhang YJ, et al. Comparison of one-year clinical outcomes between intravascular ultrasound-guided versus angiography-guided implantation of drug-eluting stents for left main lesions: a single-center analysis of a 1,016-patient cohort. Patient Prefer Adherence. 2014;8:1299–309.
20) Fröhlich GM, Redwood S, Rakhit R, et al. Long-term survival in patients undergoing percutaneous interventions with or without intracoronary pressure wire guidance or intracoronary ultrasonographic imaging: a large cohort study. JAMA Intern Med. 2014;174:1360-6.
21) Yazici HU, Agamaliyev M, Aydar Y, Goktekin O. The impact of intravascular ultrasound guidance during drug eluting stent implantation on angiographic outcomes. Eur Rev Med Pharmacol Sci. 2015;19:3012-7.
22) Singh V, Badheka AO, Arora S, et al. Comparison of inhospital mortality, length of hospitalization, costs, and vascular complications of percutaneous coronary interventions guided by ultrasound versus angiography. Am J Cardiol 2015;115:1357-66.
23) Magalhaes MA, Minha S, Torguson R, et al. The effect of complete percutaneous revascularisation with and without intravascular ultrasound guidance in the drug-eluting stent era. EuroIntervention 2015;11:625-33.
24) Nakatsuma K, Shiomi H, Morimoto T, et al; CREDO-Kyoto AMI investigators. Intravascular Ultrasound Guidance vs. Angiographic Guidance in Primary Percutaneous Coronary Intervention for ST Segment Elevation Myocardial Infarction - Long-Term Clinical Outcomes From the CREDO-Kyoto AMI Registry. Circ J 2016;80:477-84.
25) Patel Y, Depta JP, Patel JS, et al. Impact of intravascular ultrasound on the long-term clinical outcomes in the treatment of coronary ostial lesions. Catheter Cardiovasc Interv 2016;87:232-40.
26) Ahmed K, Jeong MH, Chakraborty R, et al. Role of intravascular ultrasound in patients with acute myocardial infarction undergoing percutaneous coronary intervention. Am J Cardiol. 2011;108:8-14.
27) Roy P, Torguson R, Okabe T, et al. Angiographic and procedural correlates of stent thrombosis after intracoronary implantation of drug-eluting stents. J Interv Cardiol 2007;20:307–13.
28) Gerber RT, Latib A, Ielasi A, et al. Defining a new standard for IVUS optimized drug eluting stent implantation: the PRAVIO study. Catheter Cardiovasc Interv 2009;74:348–56.
29) Biondi-Zoccai G, Sheiban I, Romagnoli E, et al. Is intravascular ultrasound beneficial for percutaneous coronary intervention of bifurcation lesions? Evidence from a 4314-patient registry. Clin Res Cardiol 2011;100:1021–8.
30) Wakabayashi K, Lindsay J, Laynez-Carnicero A, et al. Utility of intravascular ultrasound guidance in patients undergoing percutaneous coronary intervention for type C lesions. J Interv Cardiol 2012;25:452–9.
31) Patel Y, Depta JP, Novak E, et al. Long-term outcomes with use of intravascular ultrasound for the treatment of coronary bifurcation lesions. Am J Cardiol 2012;109:960–5.
32) De la Torre Hernandez JM, Alfonso F, Sanchez Recalde A, et al; ESTROFA-LM Study Group. Comparison of paclitaxel-eluting stents (Taxus) and everolimus-eluting stents (Xience) in left main coronary artery disease with 3 years follow-up (from the ESTROFA-LM registry). Am J Cardiol 2013;111:676-83.
33) Patel Y, Depta JP, Patel JS, Masrani SK, Novak E, Zajarias A, Kurz HI, Lasala JM, Bach RG, Singh J. Impact of intravascular ultrasound on the long-term clinical outcomes in the treatment of coronary ostial lesions. Catheter Cardiovasc Interv 2016;87:232-40.
34) Andell P, Karlsson S, Mohammad MA, Gotberg M, James S, Jensen J, Frobert O, Angeras O, Nilsson J, Omerovic E, Lagerqvist B, Persson J, Koul S, Erlinge D. Intravascular ultrasound guidance is associated with better outcome in patients undergoing unprotected left main coronary artery stenting compared with angigarphy guidance alone. Circ Cardiovasc Interv 2017;10:e004813.
35) Tian J, Guan C, Wang W, Zhang K, Chen J, Wu Y, Yan H, Zhao Y, Qiao S, Yang Y, Mintz GS, Xu B, Tang Y. Intravascular Ultrasound Guidance Improves the Long-term Prognosis in Patients with Unprotected Left Main Coronary Artery Disease Undergoing Percutaneous Coronary Intervention. Sci Rep. 2017 May 24;7(1):2377.
36) Prati F, Di Vito L, Biondi-Zoccai G, et al. Angiography alone versus angiography plus optical coherence tomography to guide decision-making during percutaneous coronary intervention: the Centro per la Lotta contro l'Infarto-Optimisation of Percutaneous Coronary Intervention (CLI-OPCI) study. EuroIntervention. 2012;8:823-9.
37) Wijns W, Shite J, Jones MR, et al. Optical coherence tomography imaging during percutaneous coronary intervention impacts physician decision-making: ILUMIEN I study. Eur Heart J. 2015;36:3346-55
38) Maehara A, Ben-Yehuda O, Ali Z, et al. Comparison of Stent Expansion Guided by Optical Coherence Tomography Versus Intravascular Ultrasound: The ILUMIEN II Study (Observational Study of Optical Coherence Tomography [OCT] in Patients Undergoing Fractional Flow Reserve [FFR] and Percutaneous Coronary Intervention). JACC Cardiovasc Interv. 2015;8:1704-14.
39) Iannaccone M, D'Ascenzo F, Frangieh AH, et al. Impact of an optical coherence tomography guided approach in acute coronary syndromes: A propensity matched analyssi from the international FORMIDABLE-CARDIOGROUP IV and USZ Registry. Catheter Cardiovasc Interv 2017;90:E46-E52
40) Sheth TN, Kajander OA, Lavi S, et al. Optical Coherence Tomography-Guided Percutaneous Coronary Intervention in ST-Segment-Elevation Myocardial Infarction: A Prospective Propensity-Matched Cohort of the Thrombectomy Versus Percutaneous Coronary Intervention Alone Trial. Circ Cardiovasc Interv. 2016 Apr;9(4):e003414. doi: 10.1161

Slide courtesy of Gary Mintz

IVUS Improves PCI Outcomes: Some Evidence (1)

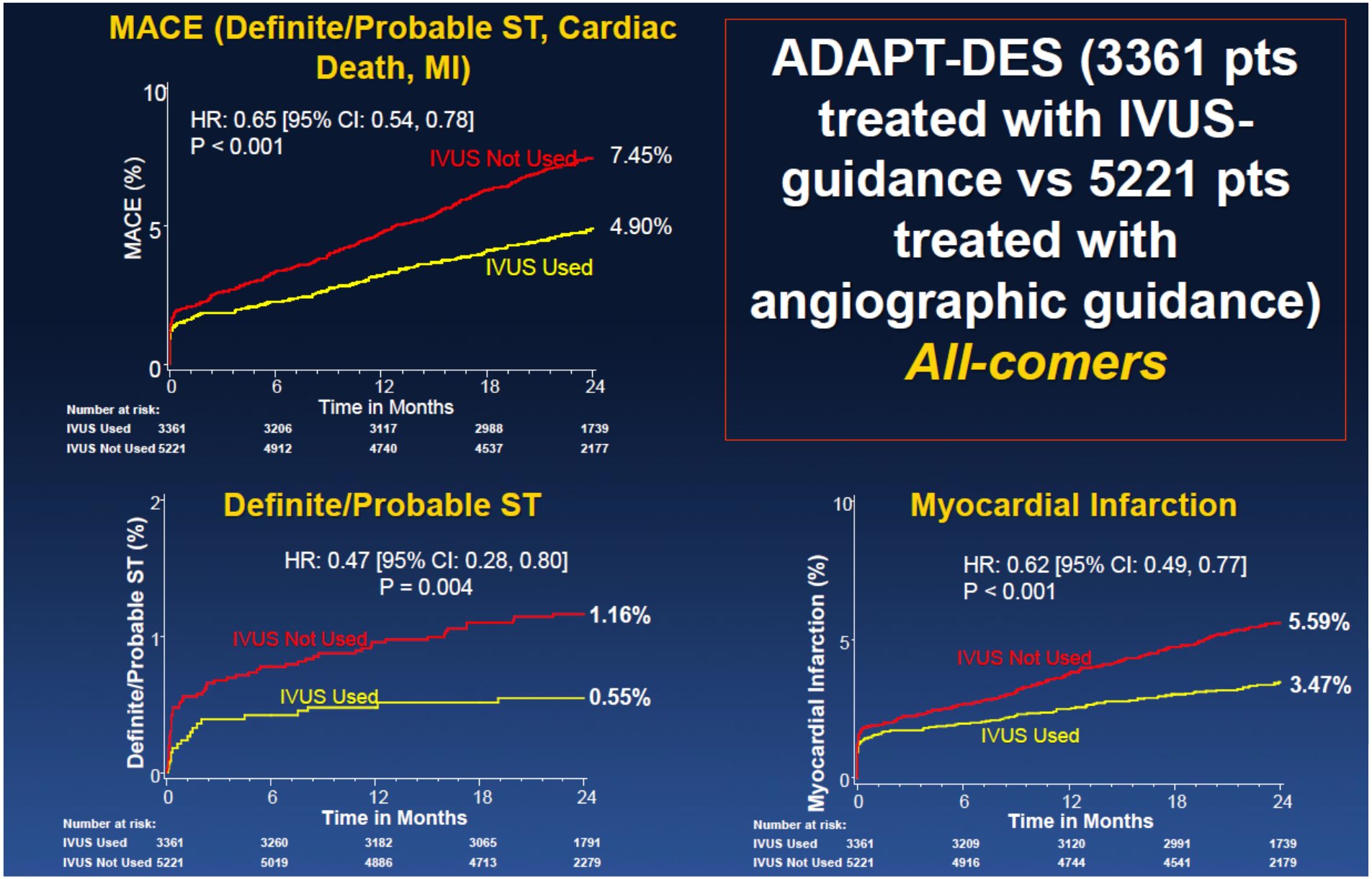

Witzenbichler B et al. Circulation 2014

IVUS Improves PCI Outcomes: Some Evidence (2)

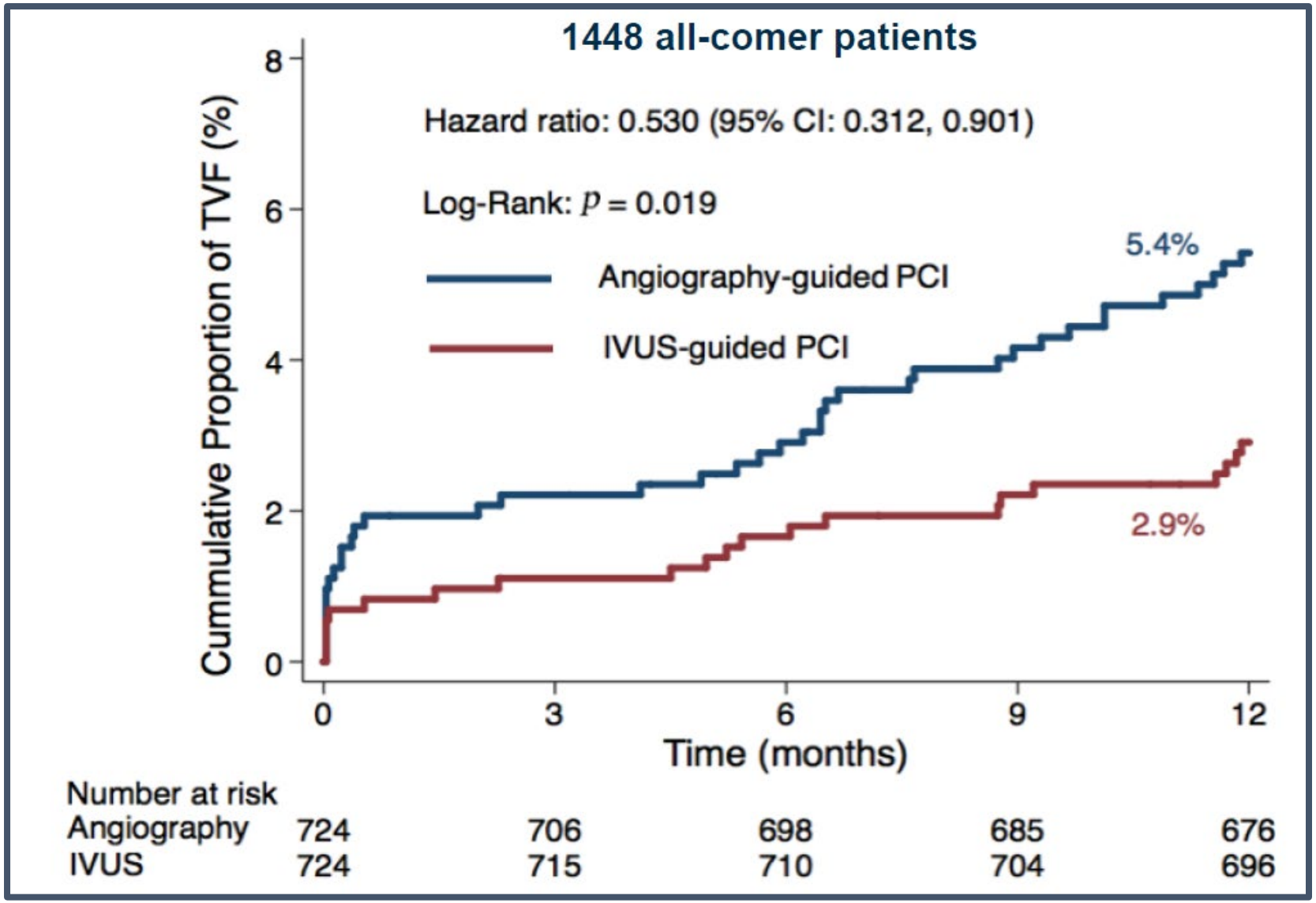

ULTIMATE TRIAL

Zhang J et al. JACC 2018

IVUS Improves PCI Outcomes: Some Evidence (2)

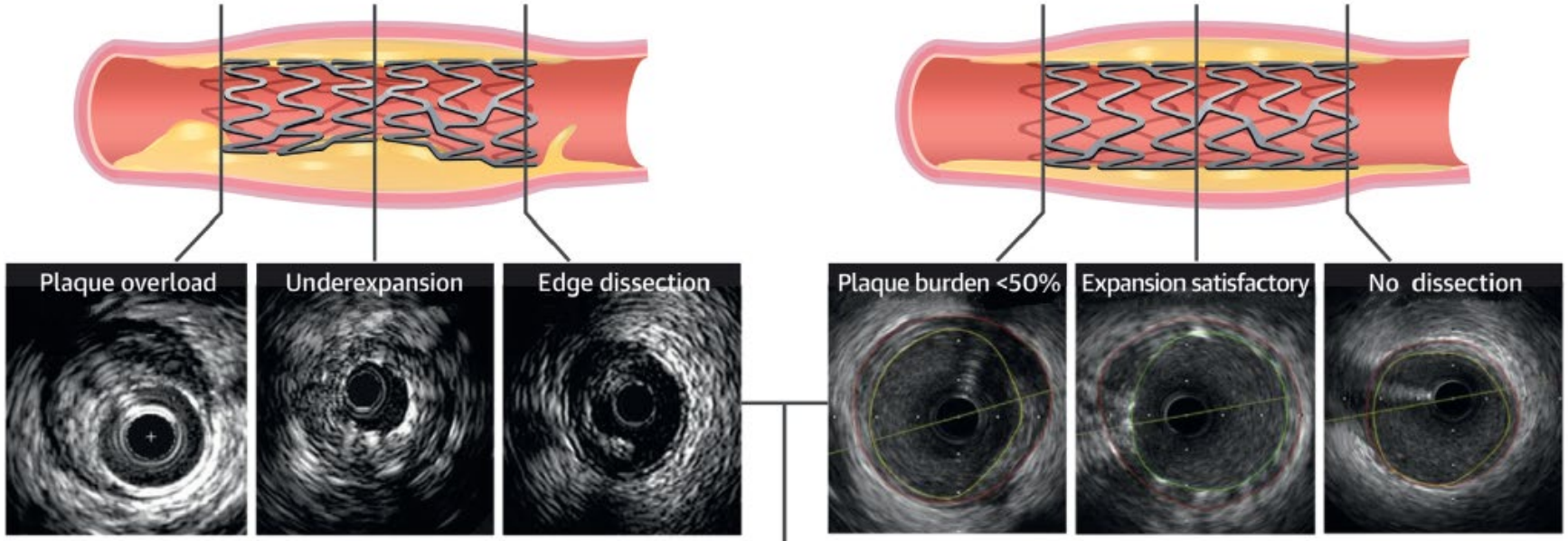

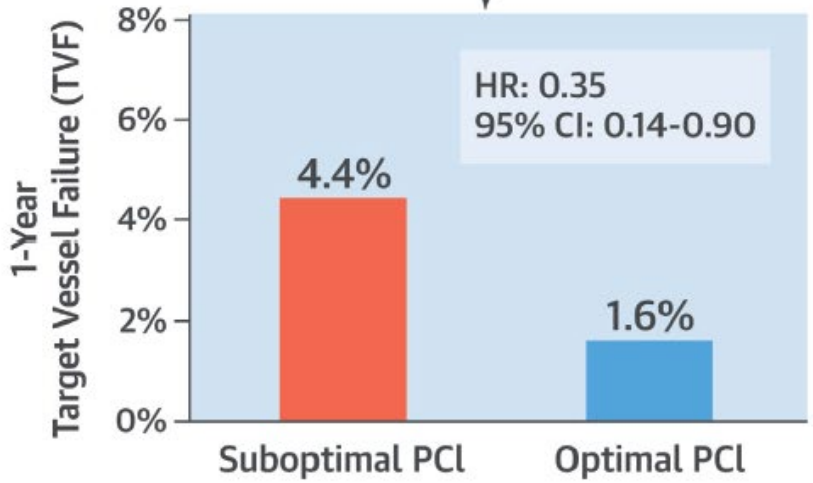

Zhang J et al. JACC 2018

ULTIMATE TRIAL

IVUS Improves PCI Outcomes: Some Evidence (3)

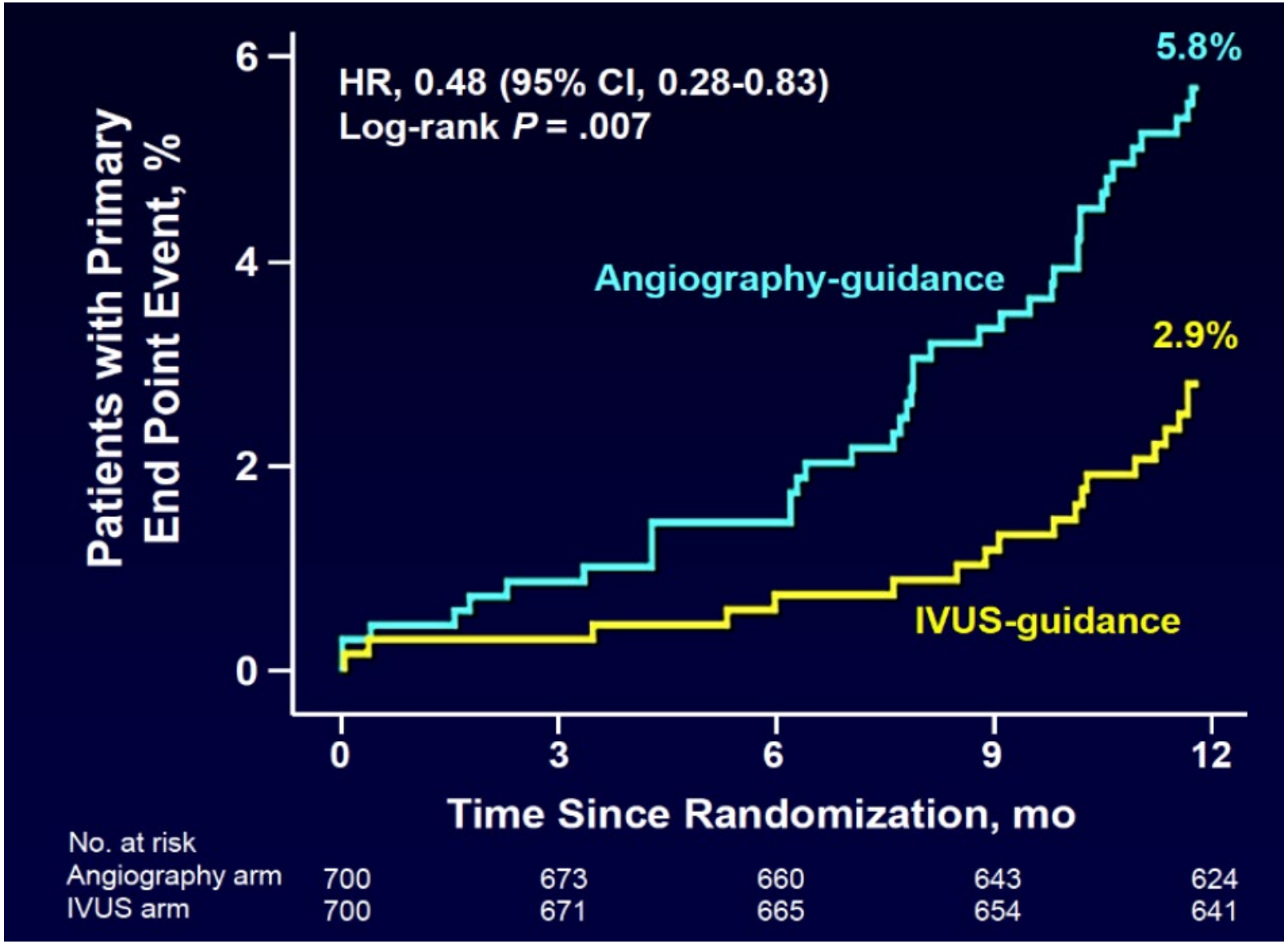

IVUS-XPL TRIAL

Hong SJ et al. JAMA 2014

IVUS Improves PCI Outcomes: Meta-analysis

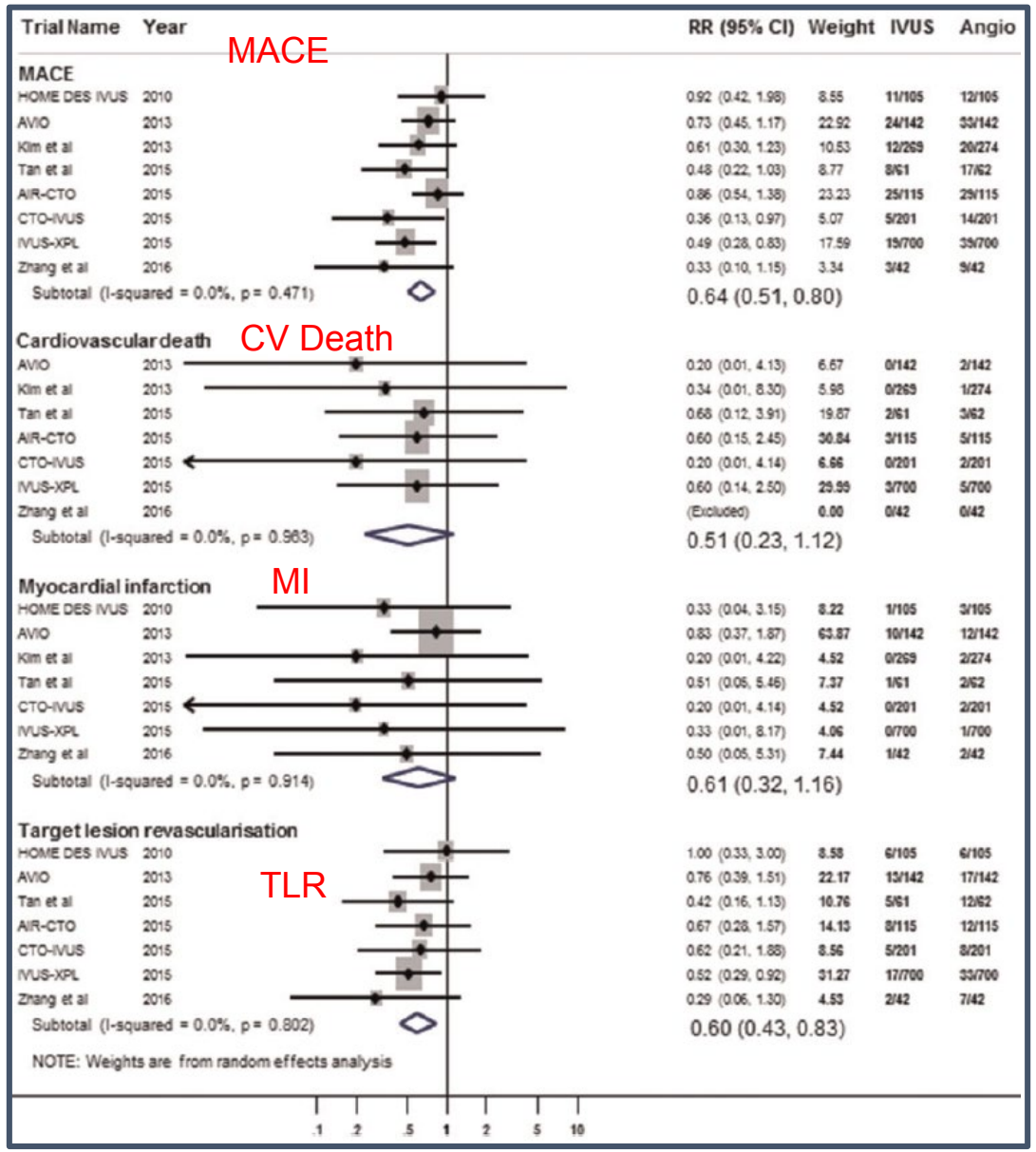

Raber L et al. Eur Heart J 2018

ILUMIEN III

Inclusion
- Single native vessel
- One or more target lesions
- RVD 2.25mm - 3.50mm
- Length < 40mm

Exclusion:
- Left main
- Ostial RCA
- CTO
- Planned bifurcation
- eGFR <30ml/min

Angiography

Identification of study lesion

Randomization to OCT-, IVUS- or angiography-guided PCI

Pre-PCI OCT	Pre-PCI IVUS	Angiography
OCT Stent Sizing Guidance, per study protocol	IVUS guided PCI, per "local standard practice"	Angiography guided PCI, per "local standard practice"
OCT guided Optimization per study protocol	IVUS guided optimization, per "local standard practice"	Angiographic optimization, per "local standard practice"
Post-PCI OCT	Post-PCI OCT, blinded to investigator	Post-PCI OCT, blinded to investigator

Procedure Complete

OCT 5.79 mm^2 [4.54, 7.34]

IVUS 5.89 mm^2 [4.67, 7.80]

97.5% one-sided CI: [-0.70, -]

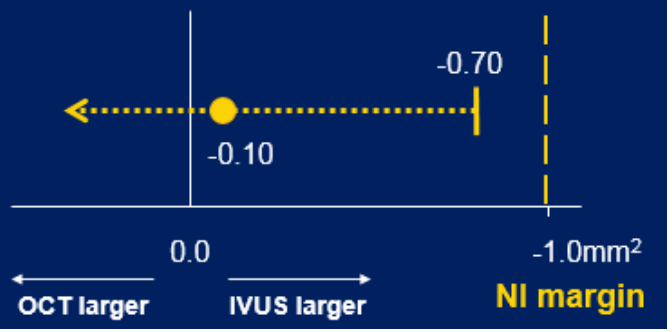

$P_{noninferiority} = 0.001$

Ali Z et al. Lancet 2016

ILUMIEN III – 1 year MACE

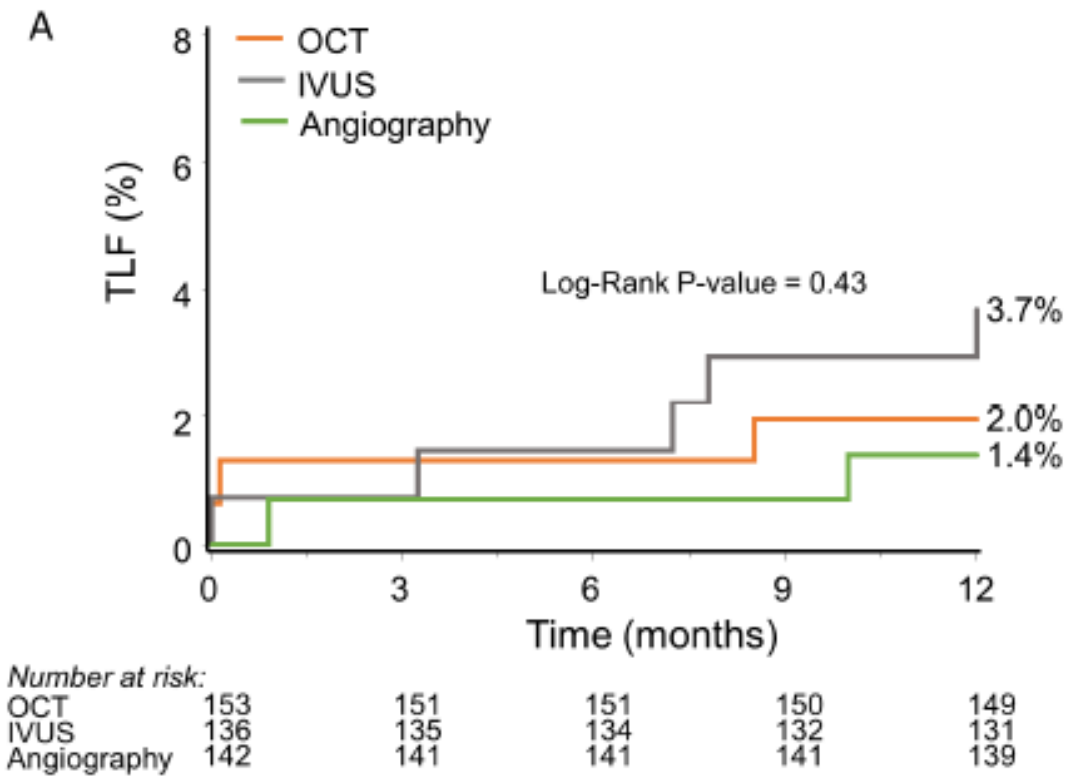

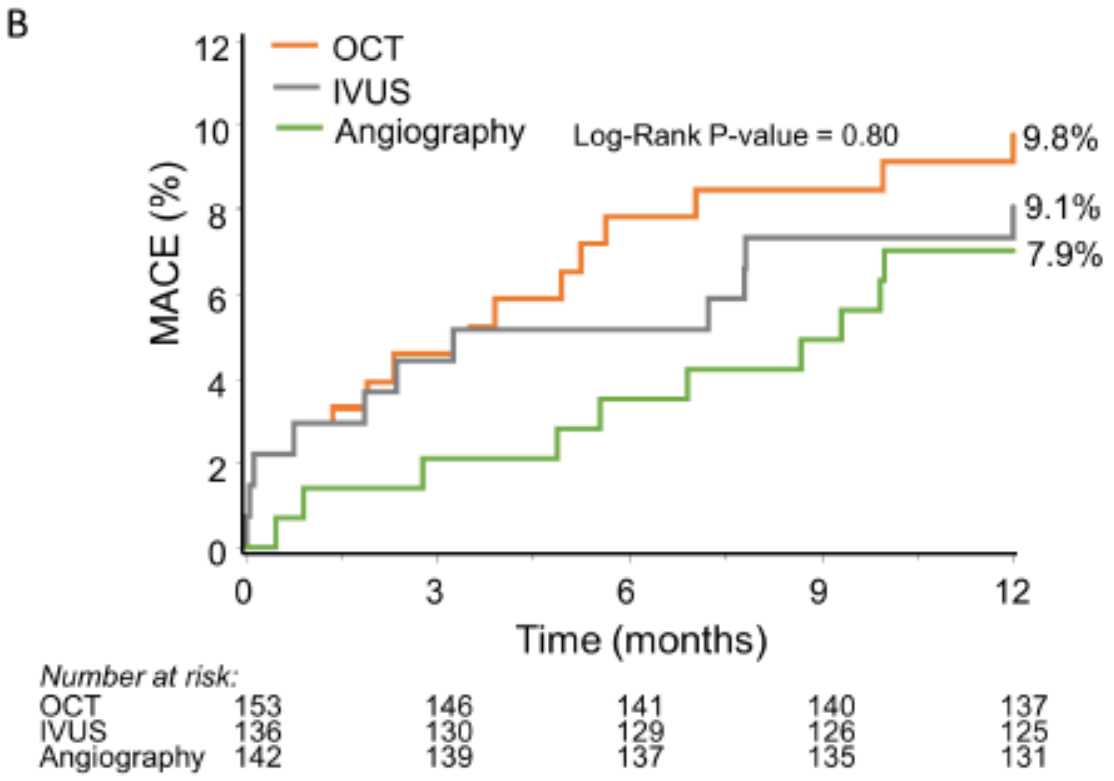

Ali Z et al. EuroIntv 2020

ILUMIEN IV

2556-3568 pts with high-risk clinical or angiographic features undergoing PCI at 125 centers in the US, Canada, Western Europe, and Asia-Pacific

HR clinical:
Diabetes
HR angio:
Troponin+ ACS culprit
Stent length ≥28 mm
2-stent bifurcation
Severe calcification
CTO
Diffuse/MF ISR

**ESRD not excluded*

Randomize 1:1

OCT-guided* PCI
(modified ILUMIEN III protocol)

Angiography-guided PCI

Final OCT (blinded in angiography arm)

Follow-up: Minimum 1 year, maximum 2 years
Primary endpoints:
1) Minimal stent area (MSA) by OCT (powered for superiority)
2) Target vessel failure (event-driven, powered for superiority)
Principal Investigators: Ziad Ali and Ulf Landmesser
Study Chair: Gregg W. Stone

Sponsor: Abbott

IVUS and OCT: ? Safe

European Heart Journal – Cardiovascular Imaging (2017) 18, 467–474
doi:10.1093/ehjci/jew037

Safety of optical coherence tomography in daily practice: a comparison with intravascular ultrasound

Johannes N. van der Sijde[1], Antonios Karanasos[1], Nienke S. van Ditzhuijzen[1],

3618 consecutive coronary imaging procedures: MACE 0%

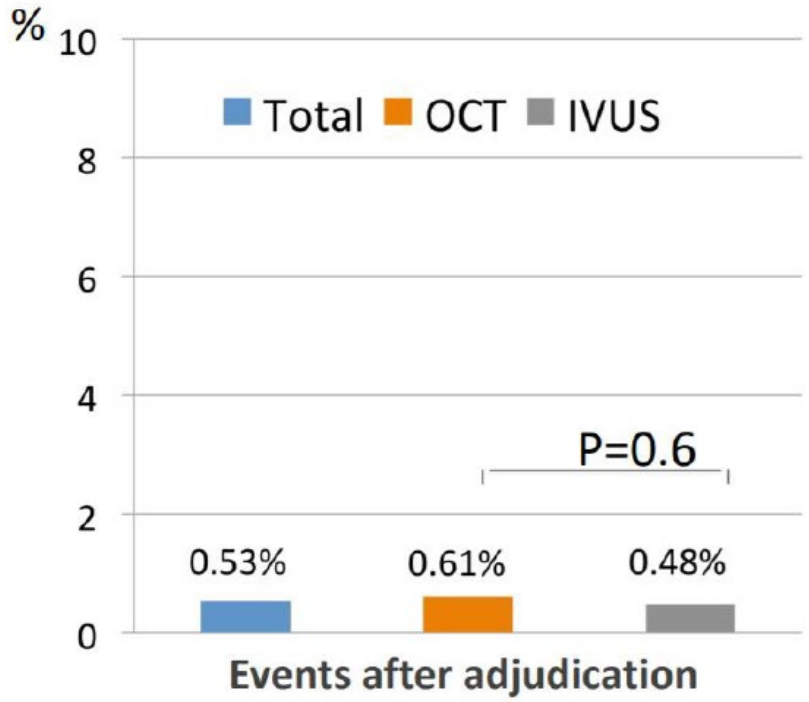

Invasive imaging complications after adjudication

	OCT	IVUS	*P*-value
Transient ST-elevation	3 (0.26)	2 (0.08)	0.2
Bradycardia	2 (0.18)	1 (0.04)	0.2
Coronary spasm	1 (0.09)	1 (0.04)	0.6
Thrombus formation	1 (0.09)	4 (0.16)	0.6
Dissection	0 (0.00)	3 (0.12)	0.2
Stent deformation	0 (0.00)	1 (0.04)	0.5
Major adverse events	0 (0.00)	0 (0.00)	NA

Values in *n* (%).

Van der Sijde et al. EHJ CV Img 2017

Intravascular Imaging Guided-PCI: Practical Strategy

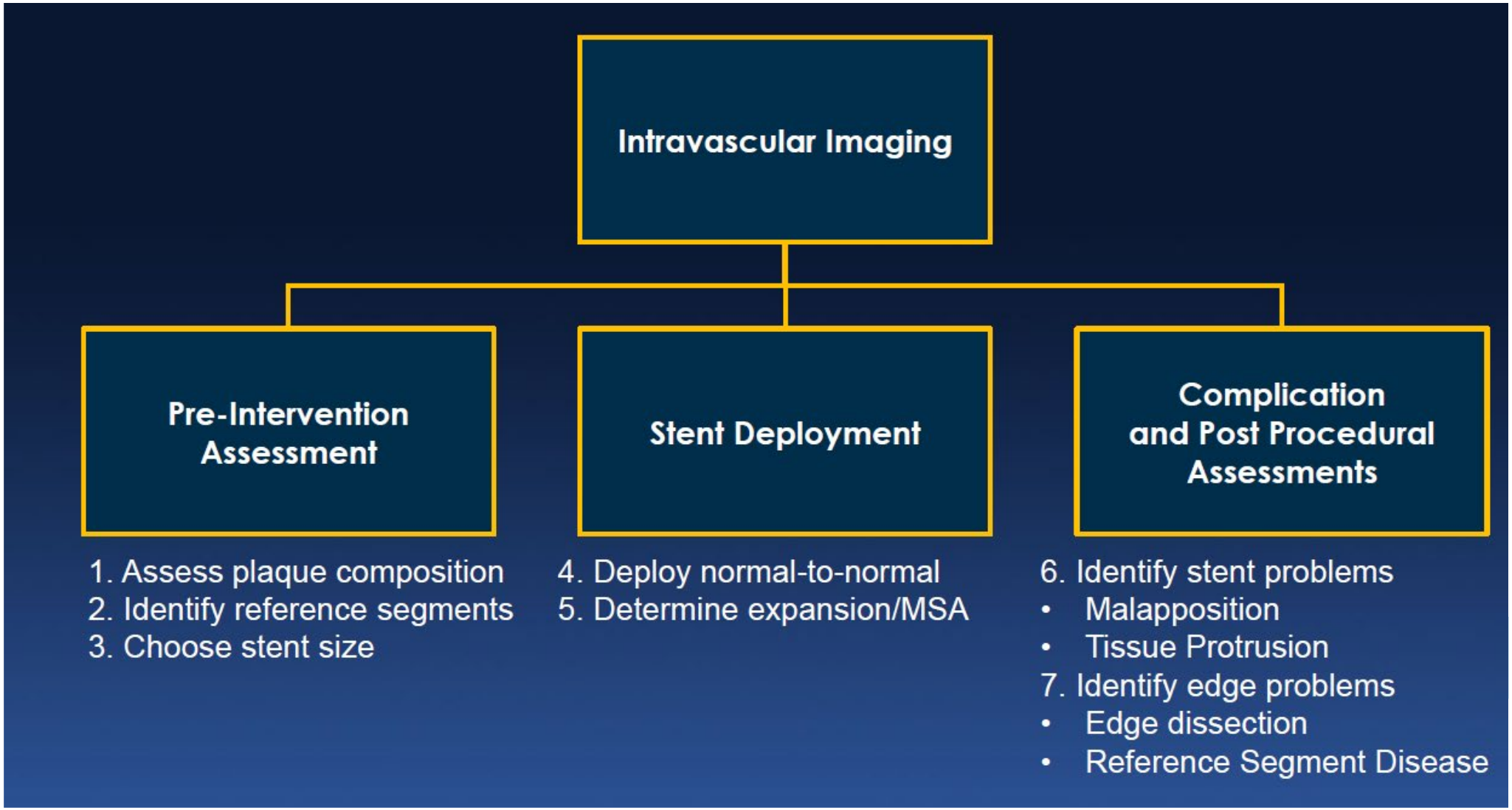

Stent Expansion Criteria (non Left Main lesions)

Study	Target
IVUS-XPL	MSA ≥distal reference lumen area
CTO-IVUS	MSA ≥distal reference lumen area > than 5mm^2 at CTO
HOME DES	MSA > than 5mm^2 or MSA ≥80% distal reference lumen area for small vessel
AVID	MSA ≥90% of distal reference lumen area
TULIP	MLD ≥80% of mean reference lumen diameters MSA ≥distal reference lumen area
OPTICUS	MSA ≥90% of mean reference lumen area or ≥100% of the reference with lowest lumen area
SIPS	MSA ≥90% of mean reference lumen area or ≥100% of the reference with lowest lumen area
RESIST	MSA ≥80% of mean reference lumen area
ILUMIEN 3	MSA ≥90% in proximal and distal reference segments relative to closest reference
OPINION	MSA ≥90% of average reference lumen area
DOCTORS	MSA ≥80% of average reference lumen area
OCTACS	MSA ≥90% of average reference lumen area

Consensus Document
MSA ≥80% of mean reference lumen area MSA > 5mm^2 by IVUS and 4.5mm^2 by OCT.

GET THE STENT MSA AS BIG AS YOU <u>REASONABLY</u> CAN

OCT Stent Sizing Algorithm

Pre-PCI OCT[1]

Measure the EEL at both proximal and distal reference segments, if possible.[2]

Can the EEL be identified at the distal reference segment to allow vessel diameter measurement?[3]

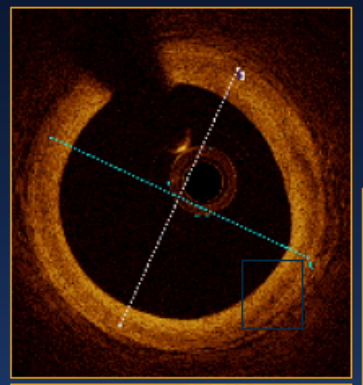

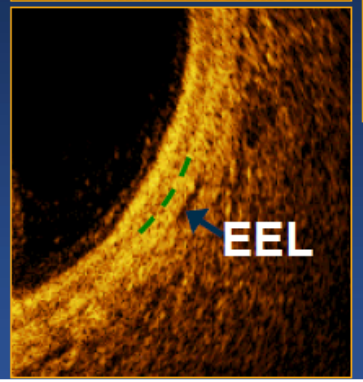

Yes

Stent diameter decided by OCT measurement of mean EEL to EEL diameter rounded down to nearest stent size[4]

No

Stent diameter decided by OCT measurement of mean lumen diameter rounded up to nearest stent size[4]

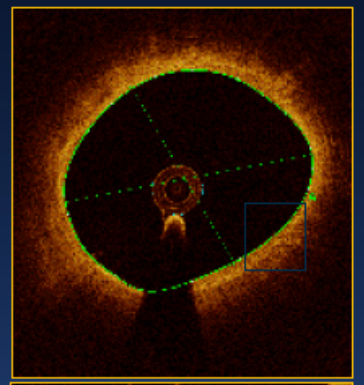

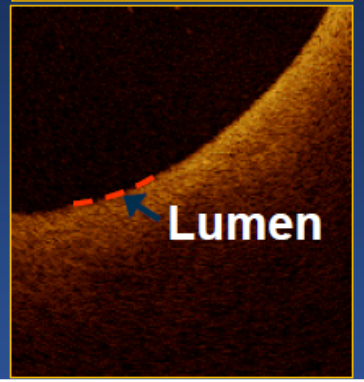

Stent length determined by OCT automation adjusted for Xience DES[5]

Adapted from slide by Ziad Ali

Stent Expansion Criteria (Left Main lesions)

EXCEL trial
1095 with unprotected LMCAD randomized to CABG vs. PCI

IVUS sub-study (n=504)

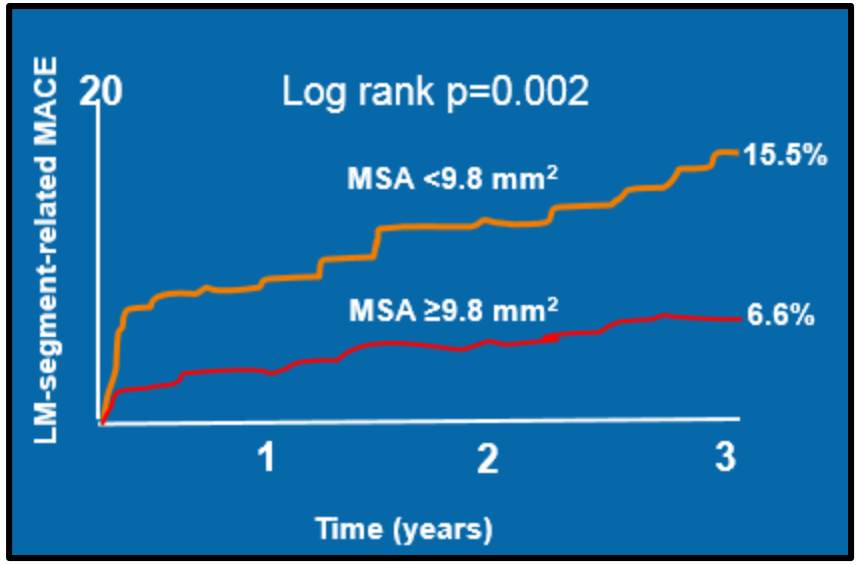

Unpublished, courtesy Gary Mintz

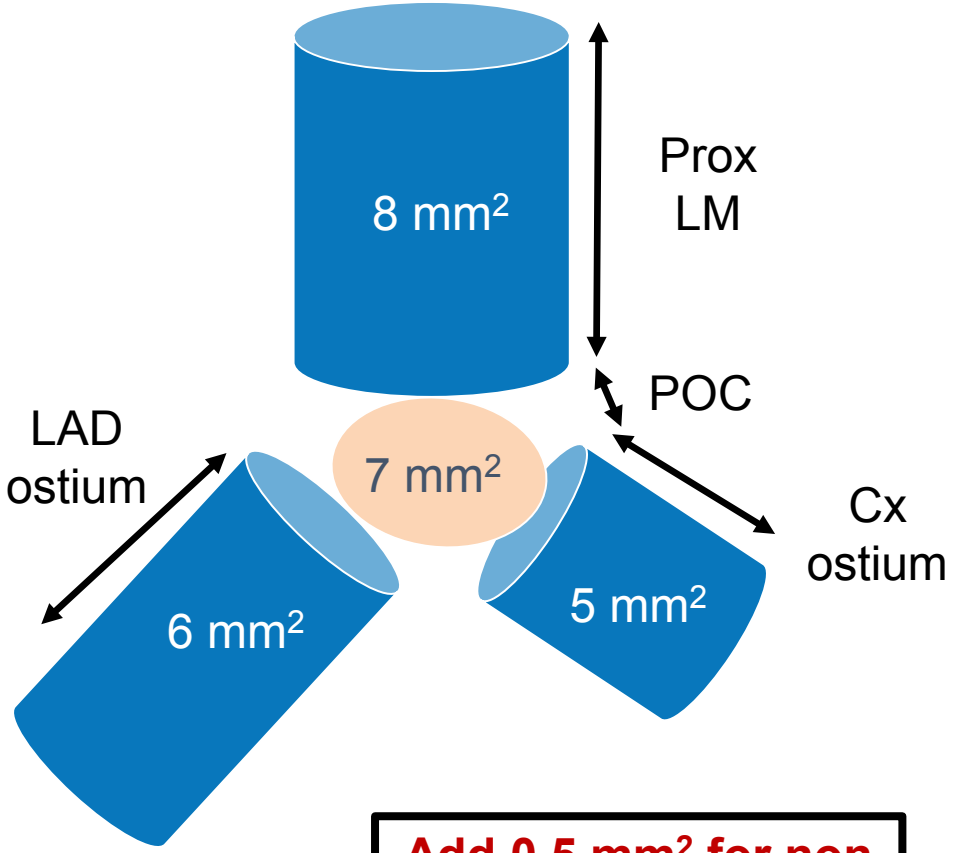

Add 0.5 mm² for non Asian or larger BSA patients

Kang et al. Circ CV Intv 2011

IVUS to Evaluate & Guide LM Lesion Severity/Revascularization

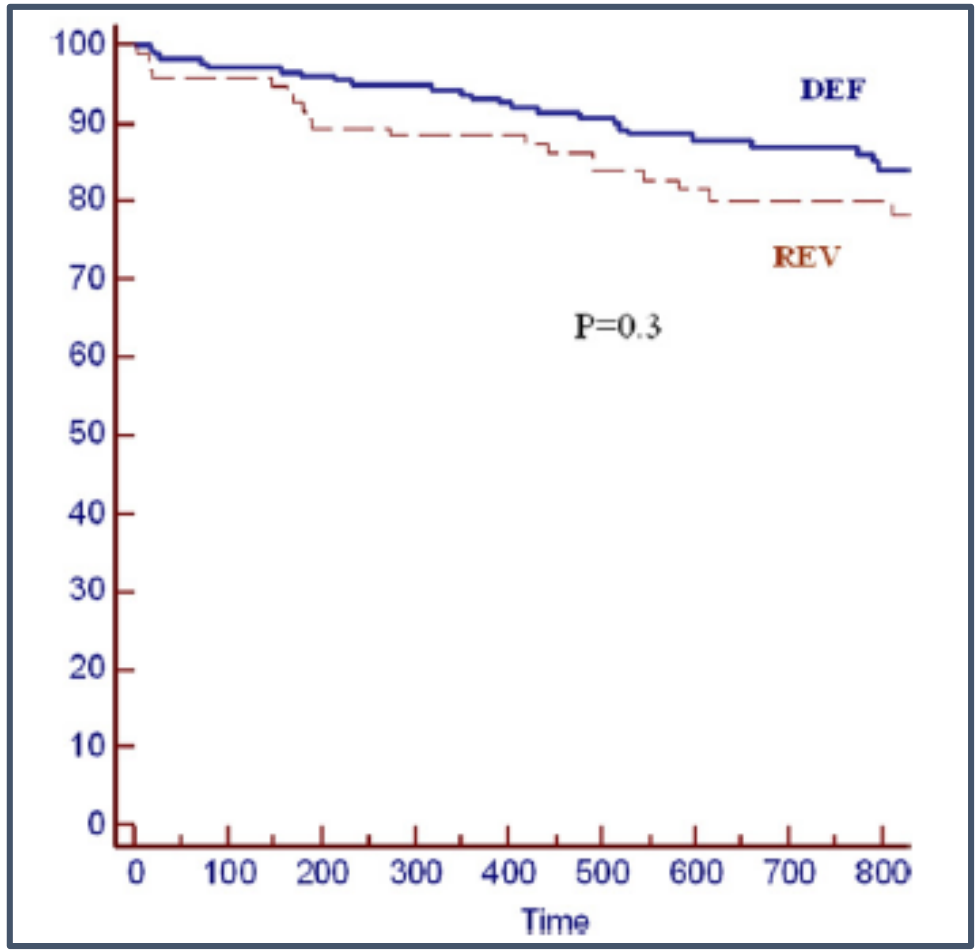

LITRO trial
354 patients, 22 Spanish centers
IVUS MLA <6mm^2 → revasc, ≤6mm^2 → defer

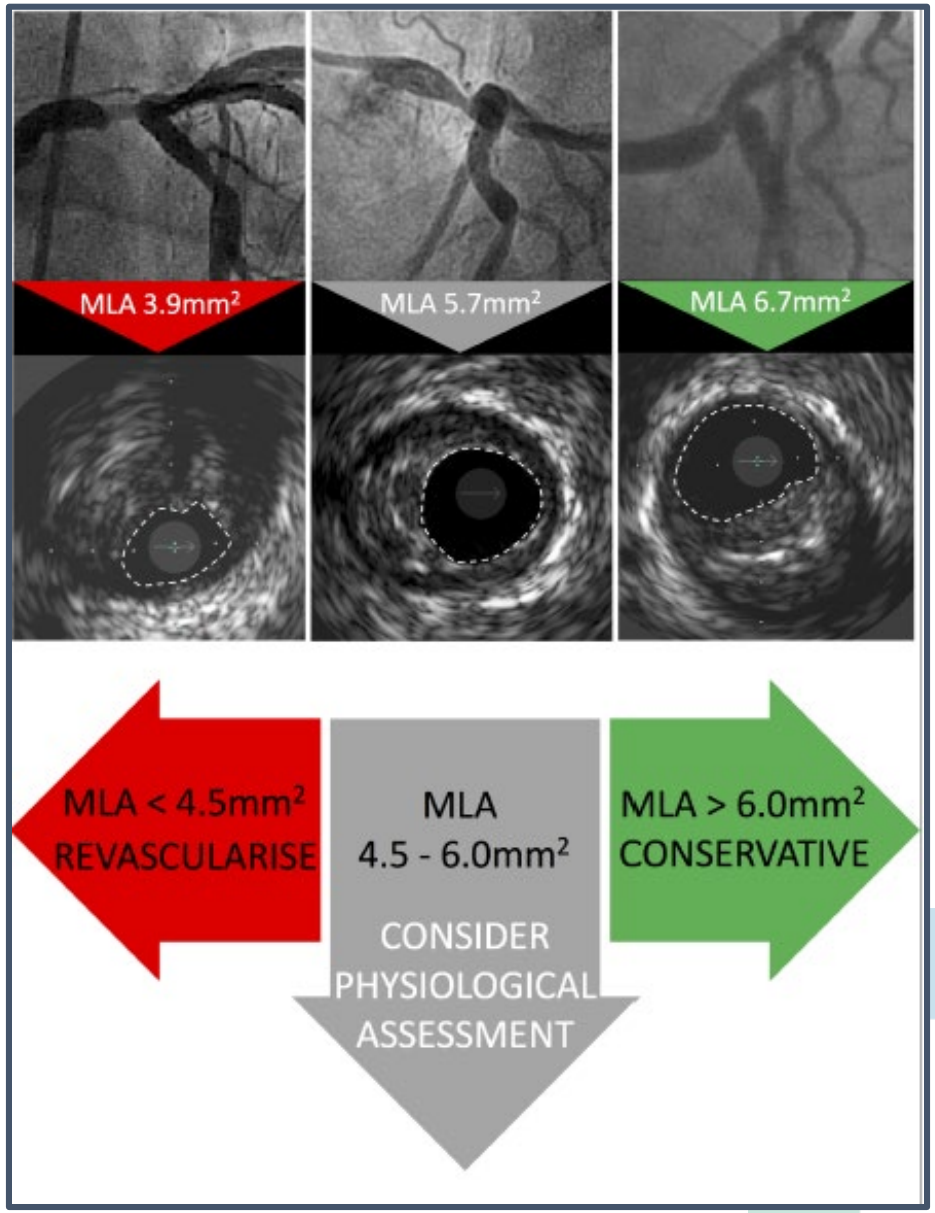

de la Torre Hernandez JM et al. JACC 2011

Plaque compositional imaging: RF-IVUS

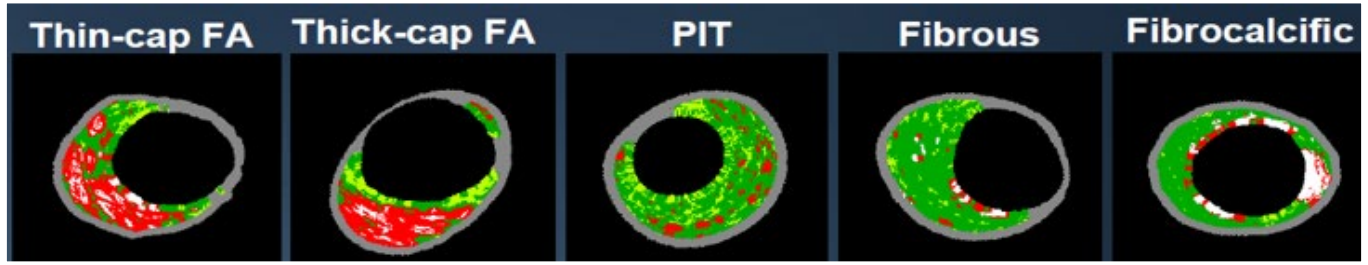

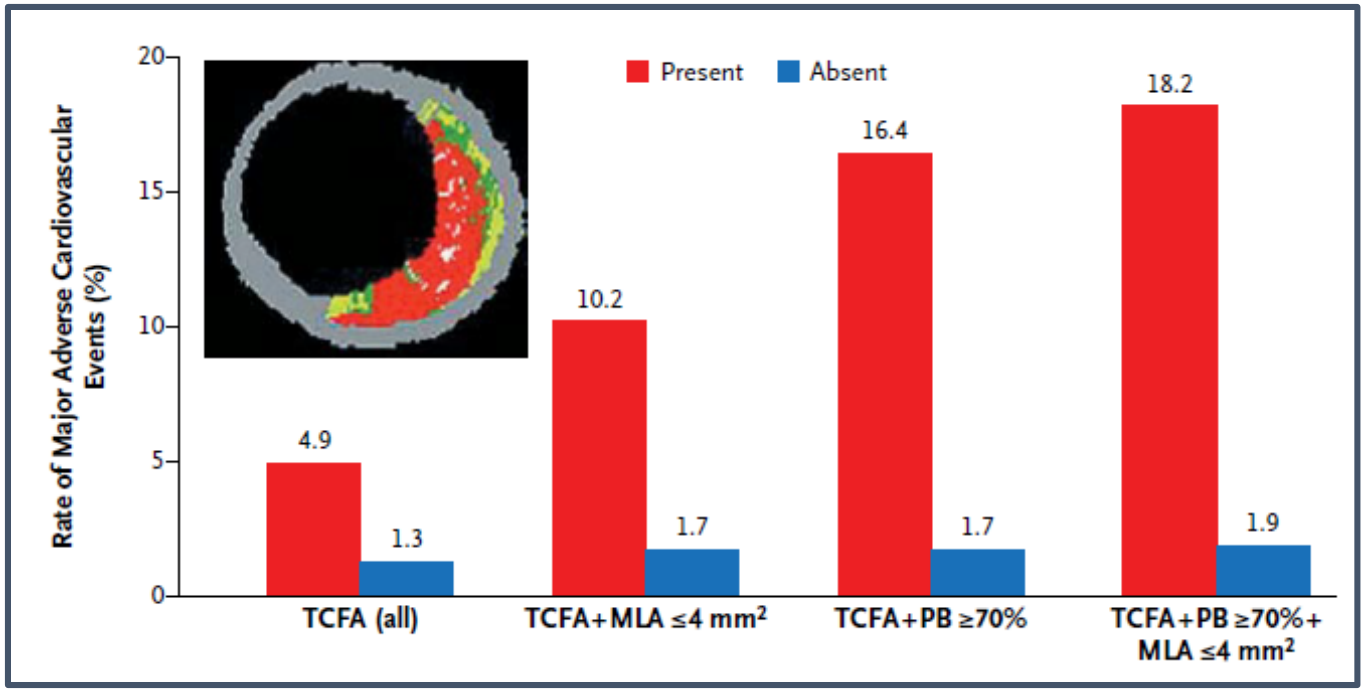

PROSPECT: VH-IVUS Natural History

20% of ACS patients developed MACE within 3-years

12% of MACE were non-culprit lesion-related MACE

VH-IVUS defined TCFA encompassing 70% PB and an MLA ≤ 4 mm^2 harbored the highest (18%) 3.4-year per lesion chance of MACE

Stone G et al. NEJM 2011

Plaque compositional imaging: NIRS-IVUS

Light + tissue → absorb, scatter, emit
NIR wavelength is 780-2,500 nm
Chemical composition of tissue
Ideal for specific lipid detection in tissue

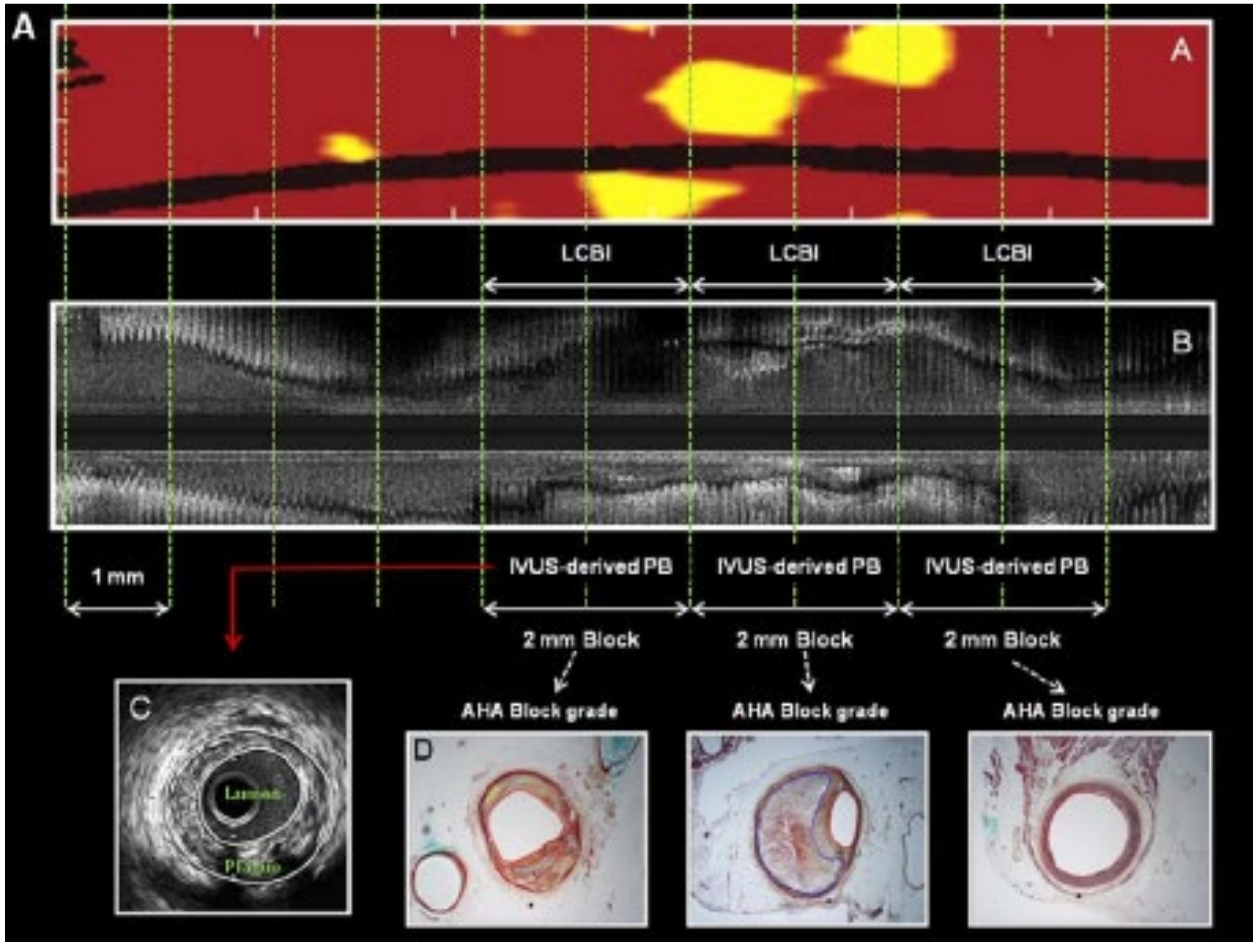

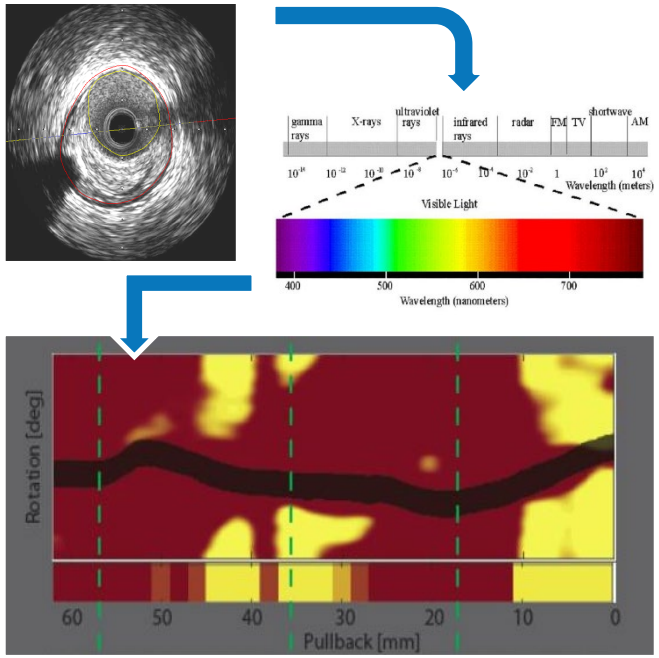

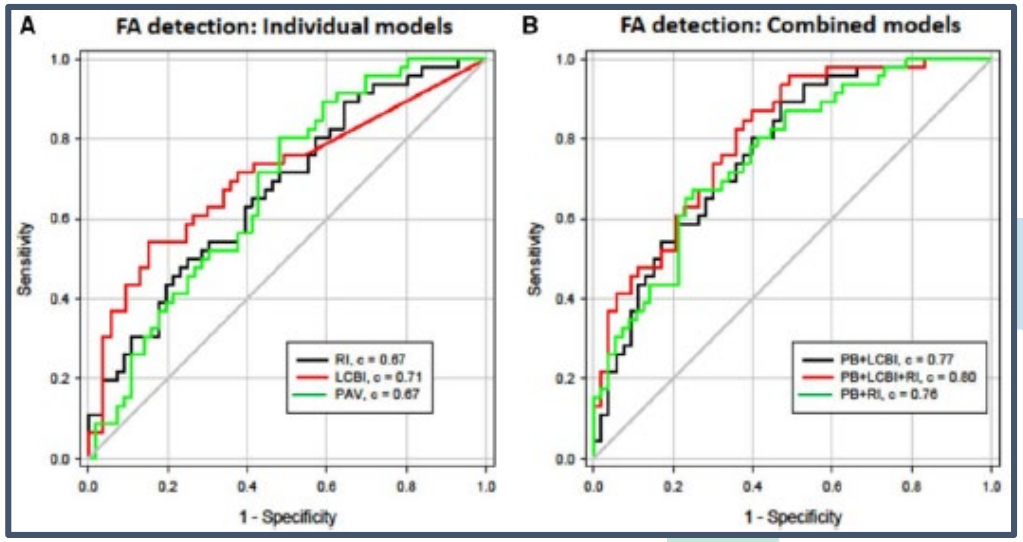

Puri R et al. ATVB 2015

Near-Infrared Spectroscopy In STEMI

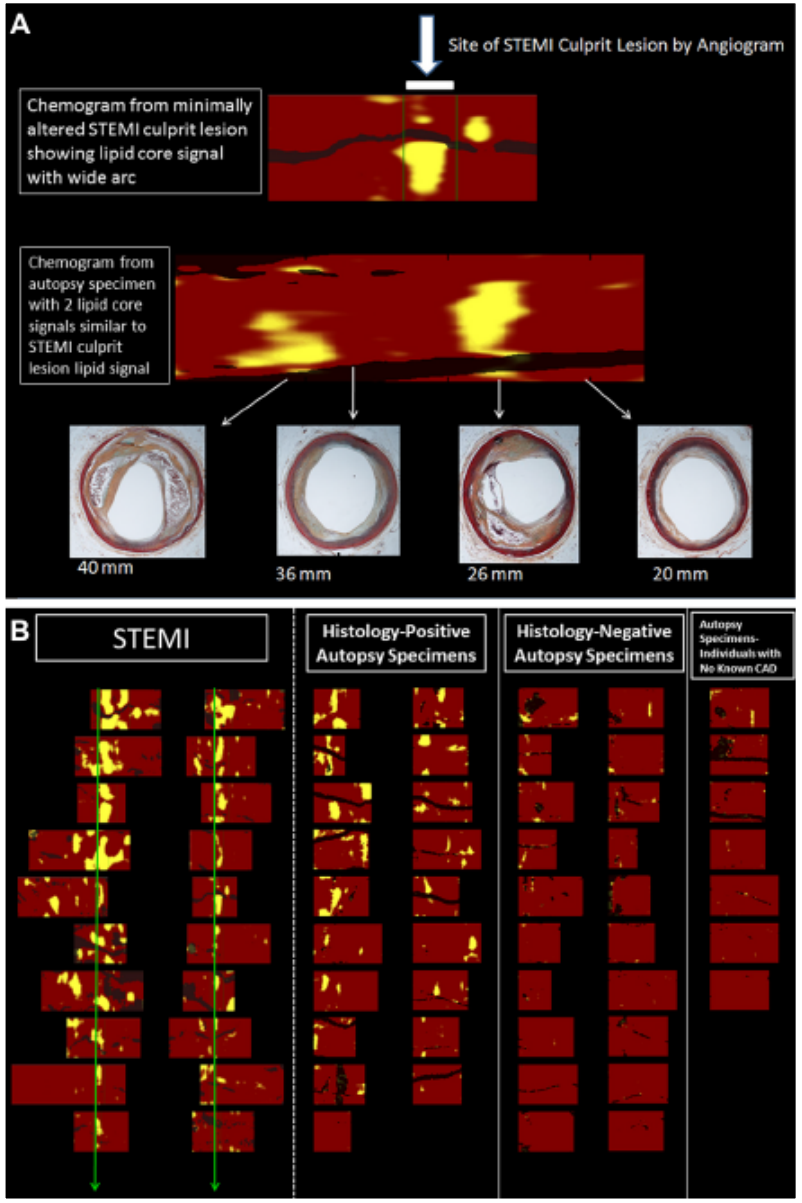

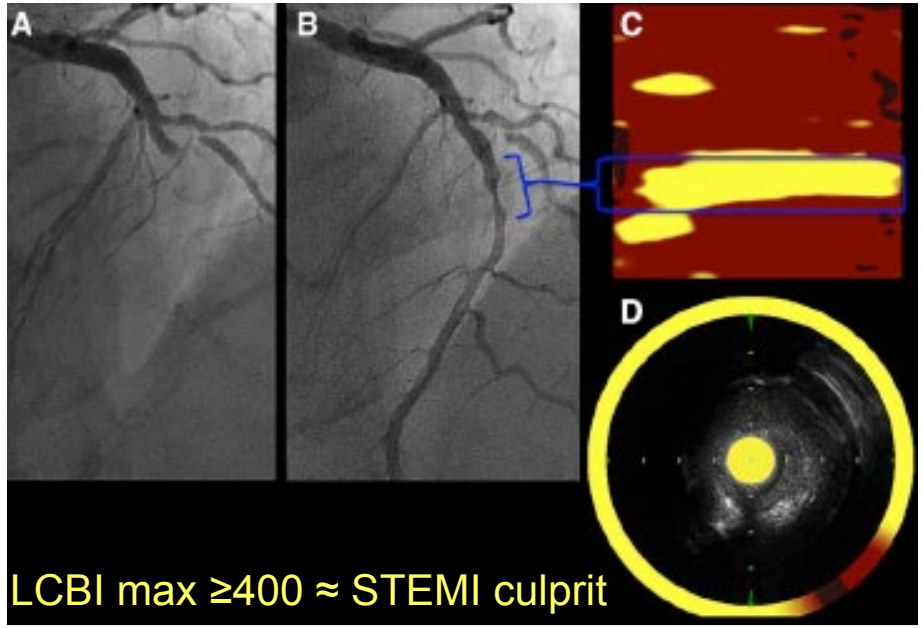

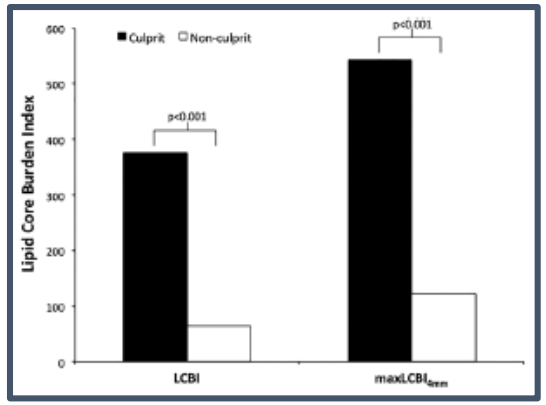

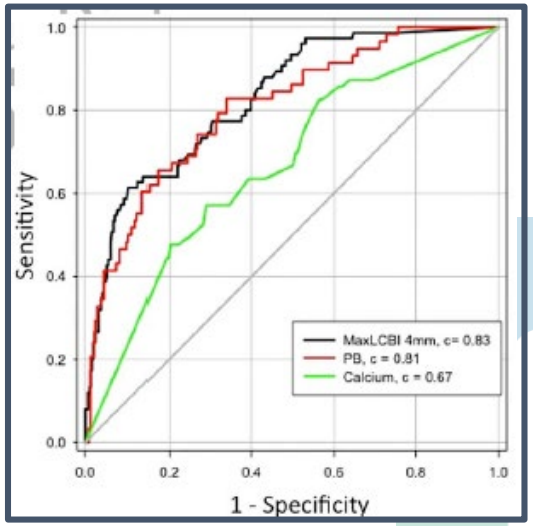

Madder R et al. JACC CV Intv 2013; Madder R et al. ATVB 2016

Case 1: Indeterminate left main and significant LAD disease (1)

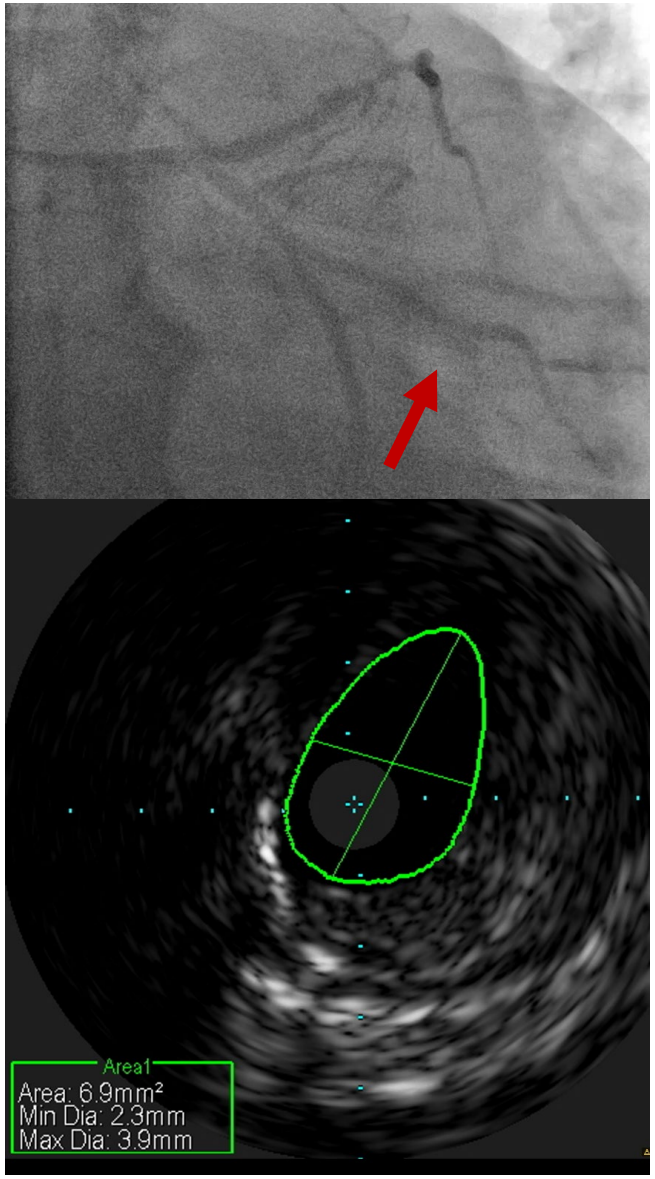

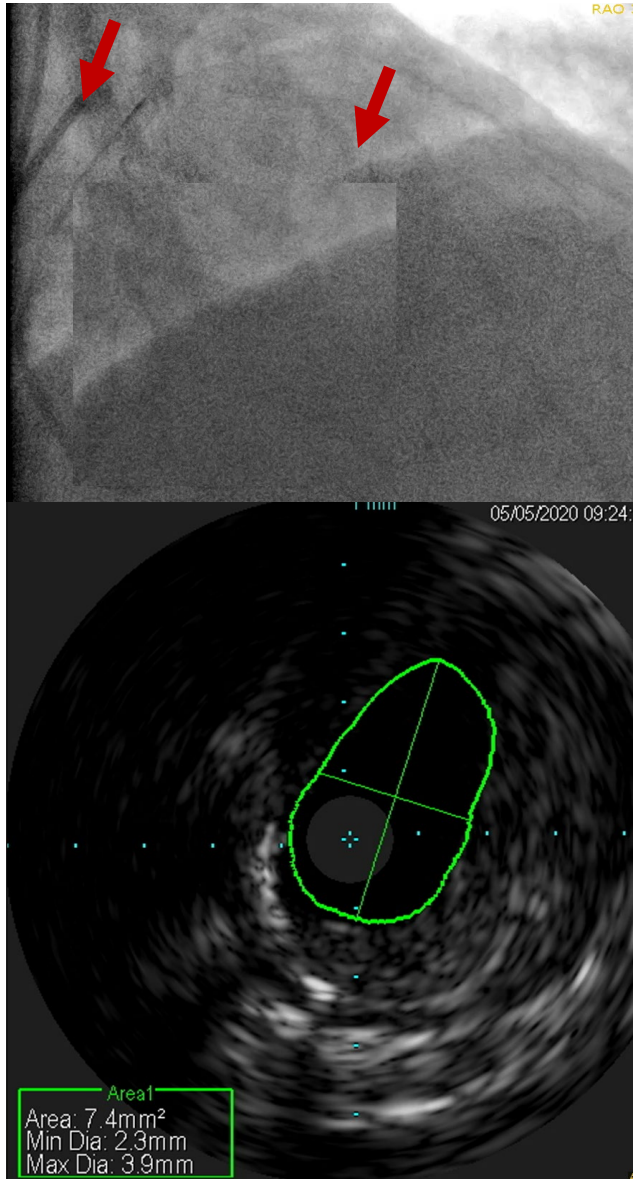

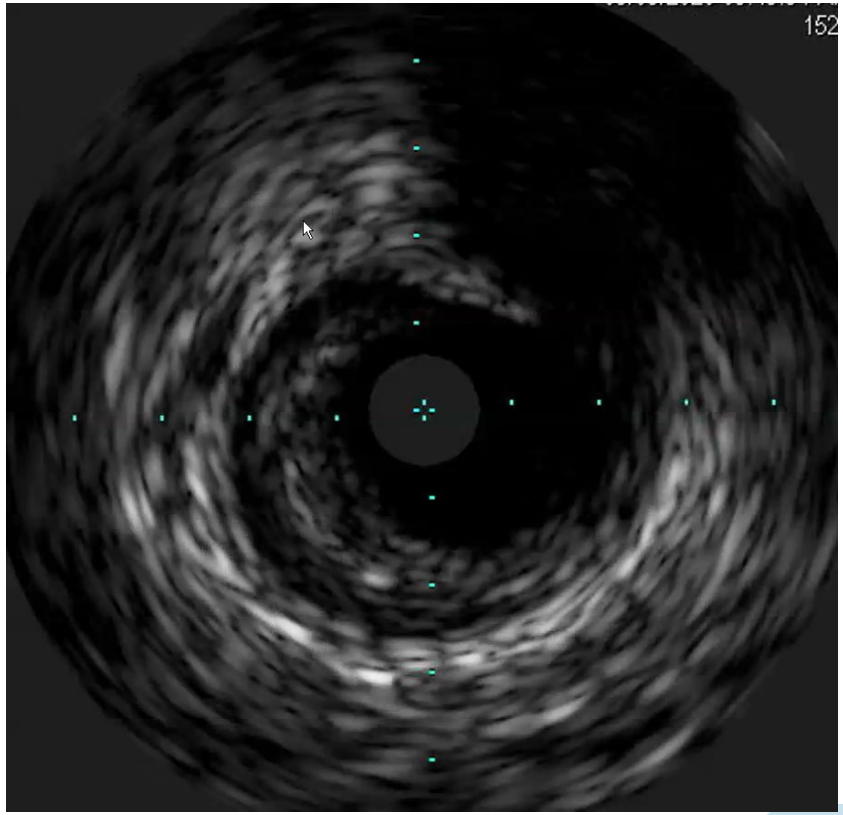

60 yo obese diabetic male, ACS (TnT +ve), cath at OSH interpreted as significant LMCA + OM1 + prox-mid LAD, anti-phospholipid syndrome on Coumadin for recurrent DVT/PE. Sent for CABG

IVUS LM: MLA >6mm2; iFR OM1 0.92-0.95, IVUS-guided PCI to LAD with 3 x 28 mm Synergy, PD with 3.5 mm NC balloon at 22A.

Case 1: Indeterminate left main and significant LAD disease (2)

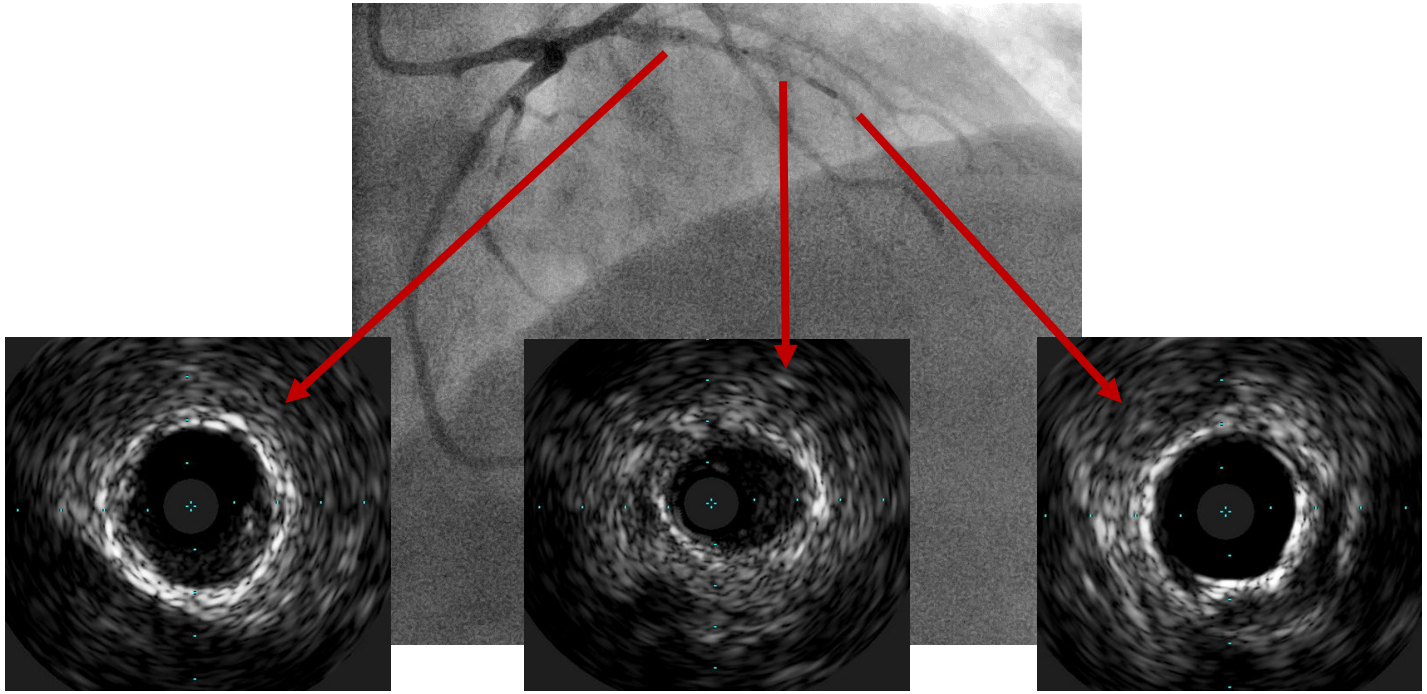

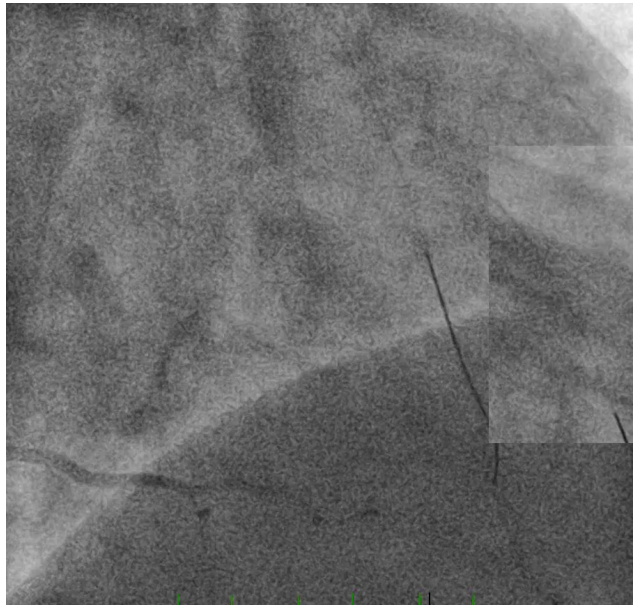

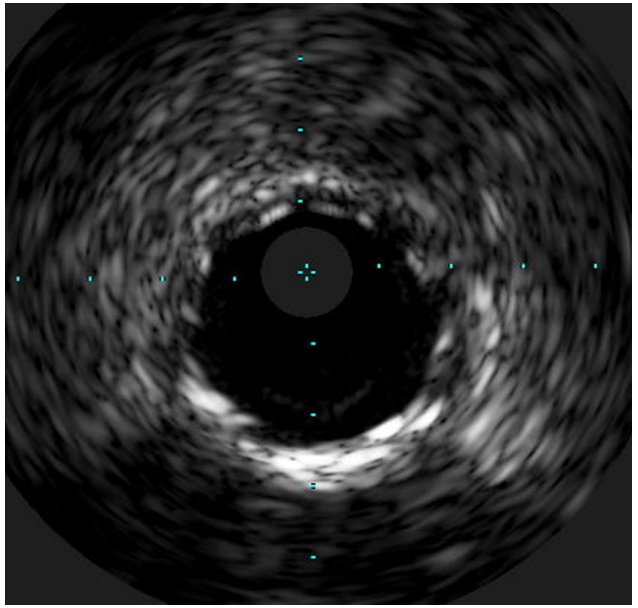

Case 2: Stenting ‘cute’ into an LAD aneurysm

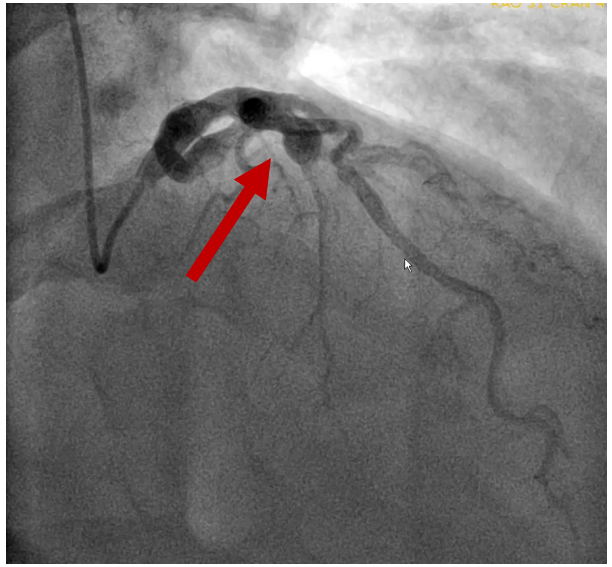

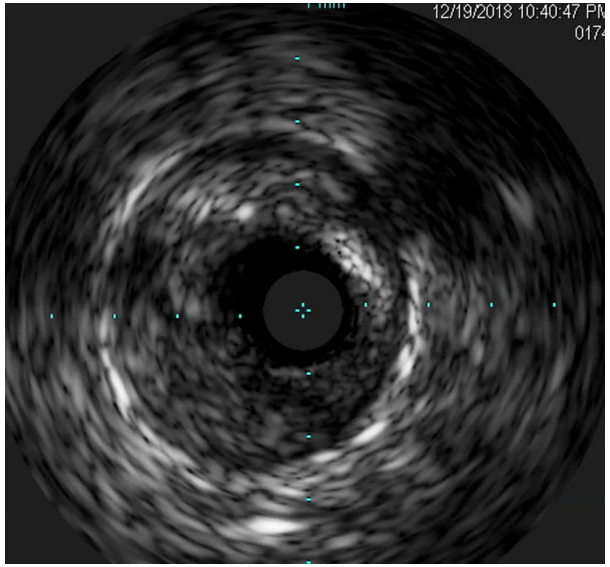

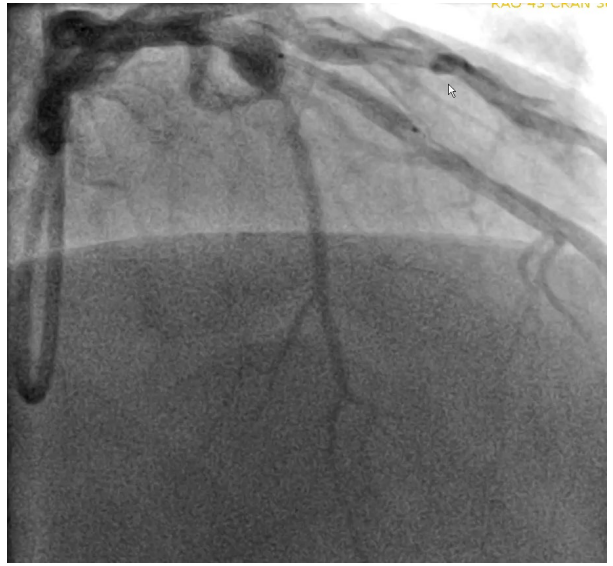

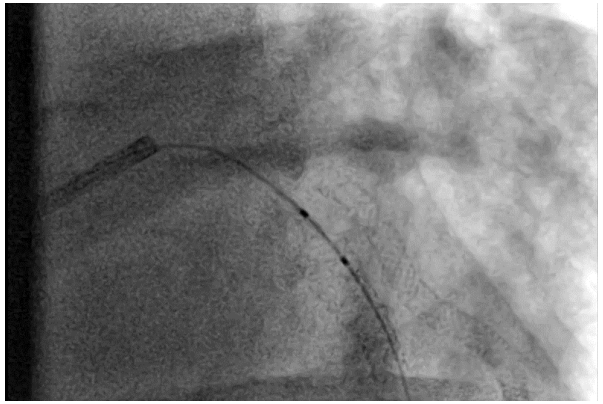

IVUS:
Aneurysm neck: 6-6.5 mm
LAD 4 mm

Rationale:
Size stent for LAD and position stent 2-3 mm into neck of aneurysm and flare with PD balloon

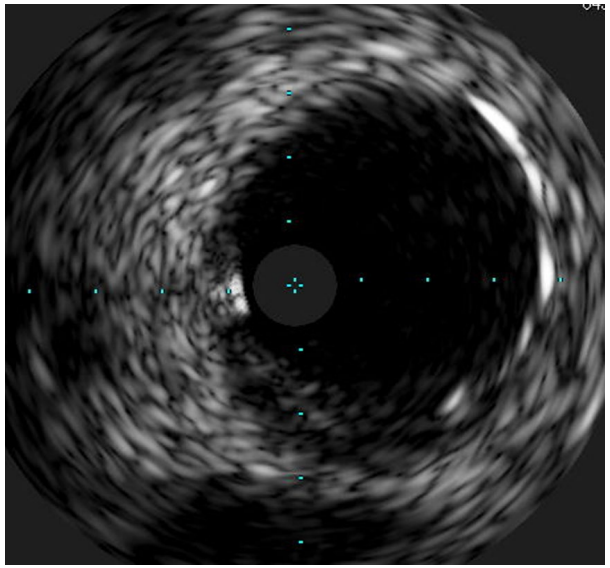

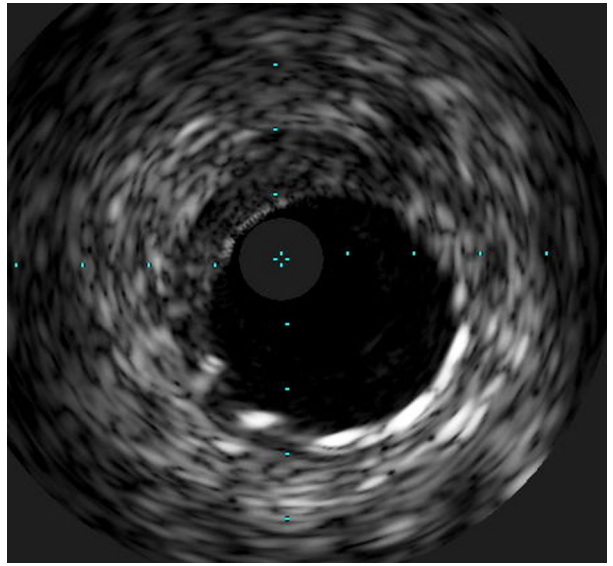

4 x 16 mm Synergy, post-dilated with a 6.0mm Emerge balloon at 22A

Some Recent Developments in IVUS

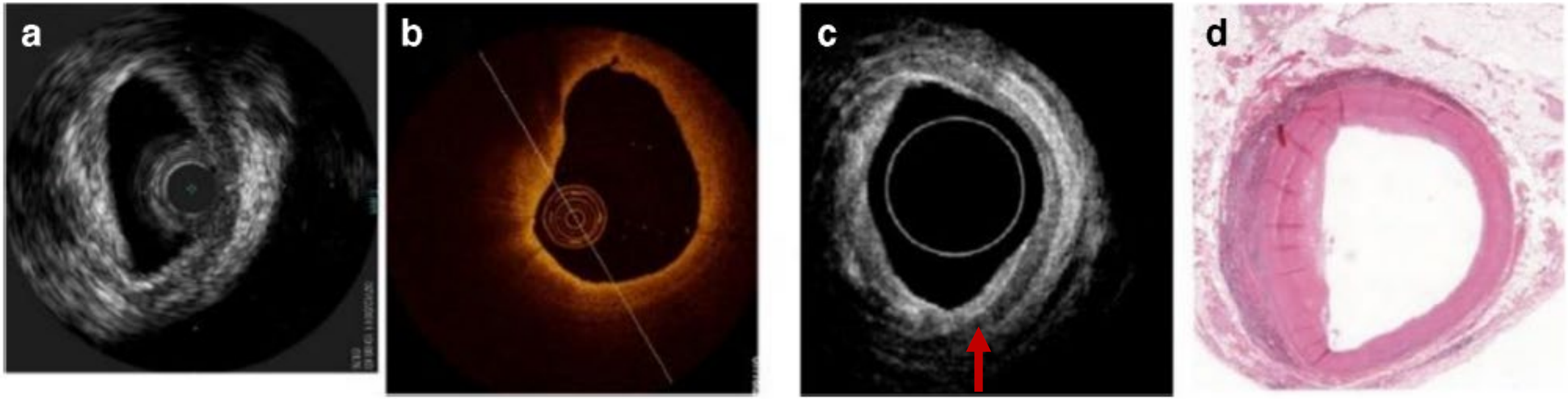

HD-IVUS

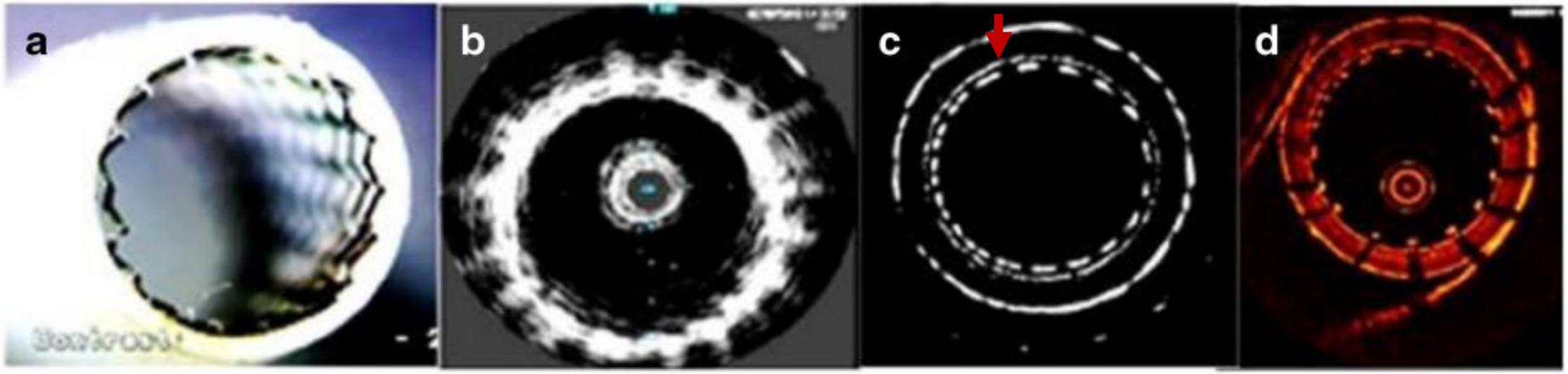

Courtesy Dr A Fleischman

Irrespective of your preference/bias between IVUS and OCT…

→ ANY USE OF INTRAVASCULAR IMAGING IS STRONGLY RECOMMENDED DURING YOUR PCIs, supported by a wealth of evidence

→ learn how to use/interpret the images you take



Cleveland Clinic
Heart & Vascular Institute

C5Research
Cleveland Clinic Coordinating Center for Clinical Research

Cleveland Clinic

Every life deserves world class care.

Thank you!

purir@ccf.org