Echo Board Review
ACC FIT: Iowa. April 2021

Evaluation of Right Ventricle & Pulmonary Hypertension

Venkata Mahesh Alla MD FACC FASE
Associate Professor of Medicine
Division of Cardiology
Creighton University School of Medicine
CHI Health Clinic Nebraska

No relevant disclosures

Objectives

1. Describe the essential echocardiographic views for assessing the right ventricle (RV)
2. List the various measures of RV function and identify abnormal values
3. Evaluate hemodynamic status of the RV and pulmonary circulation using Echocardiography

A. Use above knowledge in the evaluation & management of your patients

B. Reinforce some key test concepts as you prepare for Echo Boards


ESC European Society of Cardiology
European Heart Journal - Cardiovascular Imaging (2018) 19, 591–600
doi:10.1093/ehjci/jey042
EACVI CONSENSUS DOCUMENT

Standardization of left atrial, right ventricular, and right atrial deformation imaging using two-dimensional speckle tracking echocardiography: a consensus document of the EACVI/ASE/Industry Task Force to standardize deformation imaging

Luigi P. Badano[1*†], Theodore J. Kolias[2†], Denisa Muraru[1], Theodore P. Abraham[3], Gerard Aurigemma[4], Thor Edvardsen[5], Jan D'Hooge[6], Erwan Donal[7], Alan G. Fraser[8], Thomas Marwick[9,10], Luc Mertens[11], Bogdan A. Popescu[12], Partho P. Sengupta[13], Patrizio Lancellotti[14,15], James D. Thomas[16], and Jens-Uwe Voigt[17]

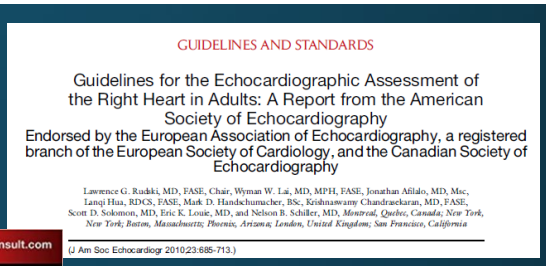
GUIDELINES AND STANDARDS

Guidelines for the Echocardiographic Assessment of the Right Heart in Adults: A Report from the American Society of Echocardiography
Endorsed by the European Association of Echocardiography, a registered branch of the European Society of Cardiology, and the Canadian Society of Echocardiography

Lawrence G. Rudski, MD, FASE, Chair, Wyman W. Lai, MD, MPH, FASE, Jonathan Afilalo, MD, Msc, Lanqi Hua, RDCS, FASE, Mark D. Handschumacher, BSc, Krishnaswamy Chandrasekaran, MD, FASE, Scott D. Solomon, MD, Eric K. Louie, MD, and Nelson B. Schiller, MD, *Montreal, Quebec, Canada; New York, New York; Boston, Massachusetts; Phoenix, Arizona; London, United Kingdom; San Francisco, California*

(J Am Soc Echocardiogr 2010;23:685-713.)



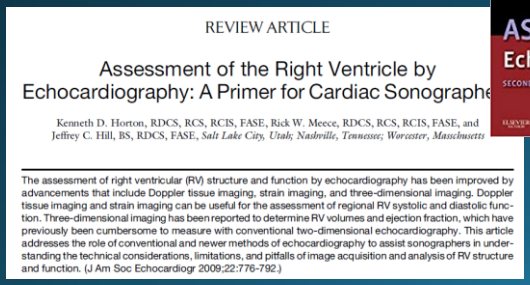
REVIEW ARTICLE

Assessment of the Right Ventricle by Echocardiography: A Primer for Cardiac Sonographe

Kenneth D. Horton, RDCS, RCS, RCIS, FASE, Rick W. Meece, RDCS, RCS, RCIS, FASE, and Jeffrey C. Hill, BS, RDCS, FASE, *Salt Lake City, Utah; Nashville, Tennessee; Worcester, Massachusetts*

The assessment of right ventricular (RV) structure and function by echocardiography has been improved by advancements that include Doppler tissue imaging, strain imaging, and three-dimensional imaging. Doppler tissue imaging and strain imaging can be useful for the assessment of regional RV systolic and diastolic function. Three-dimensional imaging has been reported to determine RV volumes and ejection fraction, which have previously been cumbersome to measure with conventional two-dimensional echocardiography. This article addresses the role of conventional and newer methods of echocardiography to assist sonographers in understanding the technical considerations, limitations, and pitfalls of image acquisition and analysis of RV structure and function. (J Am Soc Echocardiogr 2009;22:776-792.)

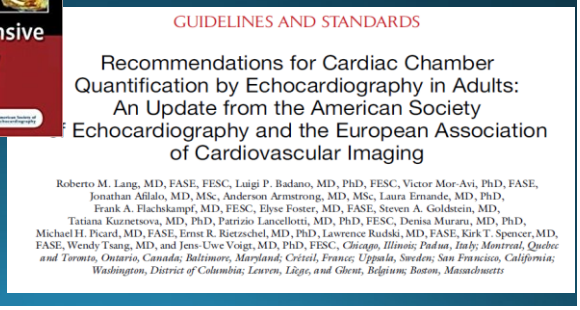
GUIDELINES AND STANDARDS

Recommendations for Cardiac Chamber Quantification by Echocardiography in Adults: An Update from the American Society Echocardiography and the European Association of Cardiovascular Imaging

Roberto M. Lang, MD, FASE, FESC, Luigi P. Badano, MD, PhD, FESC, Victor Mor-Avi, PhD, FASE, Jonathan Afilalo, MD, MSc, Anderson Armstrong, MD, MSc, Laura Ernande, MD, PhD, Frank A. Flachskampf, MD, FESC, Elyse Foster, MD, FASE, Steven A. Goldstein, MD, Tatiana Kuznetsova, MD, PhD, Patrizio Lancellotti, MD, PhD, FESC, Denisa Muraru, MD, PhD, Michael H. Picard, MD, FASE, Ernst R. Rietzschel, MD, PhD, Lawrence Rudski, MD, FASE, Kirk T. Spencer, MD, FASE, Wendy Tsang, MD, and Jens-Uwe Voigt, MD, PhD, FESC, *Chicago, Illinois; Padua, Italy; Montreal, Quebec and Toronto, Ontario, Canada; Baltimore, Maryland; Créteil, France; Uppsala, Sweden; San Francisco, California; Washington, District of Columbia; Leuven, Liège, and Ghent, Belgium; Boston, Massachusetts*

Question 1

Which of the following statements regarding Echocardiographic assessment of the right ventricle is true?

A. TAPSE is a more reliable marker of RV systolic function than FAC in post cardiac surgery patients
B. Aging is associated with a decline in RV ejection fraction
C. RV Tei index (RIMP) is a load independent measure of RV function
D. All of the above statements are true
E. None of the above is true

Question 2

Which of the following is least compatible with a diagnosis of arrhythmogenic RV cardiomyopathy?

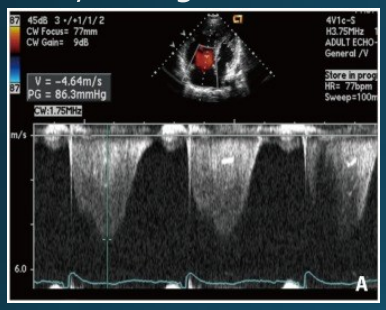

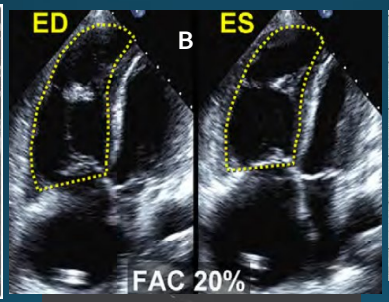

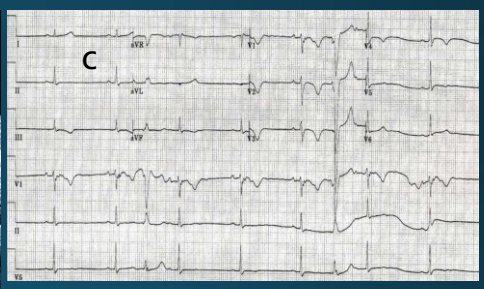

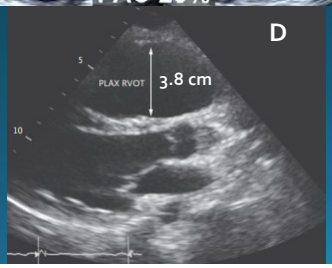

Question 3

- Which of the following patients has the highest right atrial pressure ?

	IVC Maximal diameter	IVC minimal diameter	Hepatic vein systolic filling fraction
A	1.5	0.6	65%
B	2.2	1.0	56%
C	1.8	1.1	40%
D	2.0	1.0	59%

Question 4

- Further evaluation for pulmonary hypertension is most appropriate in ?

A. Patient with Pulmonary acceleration time of 128 msec
B. Patient with Peak TR velocity of 2.8 m/sec and RVOT VTI of 21
C. Patient with early diastolic PR velocity of 2.7 m and normal IVC
D. Patient with end diastolic PR velocity of 1 m, peak TR velocity of 2.5 m/s and dilated but collapsing IVC
E. None of the above

The "neglected" ventricle

RV: A number of unique challenges!

- Anatomic
- Physiologic
- Technical

Technical

- Shielded by Sternum

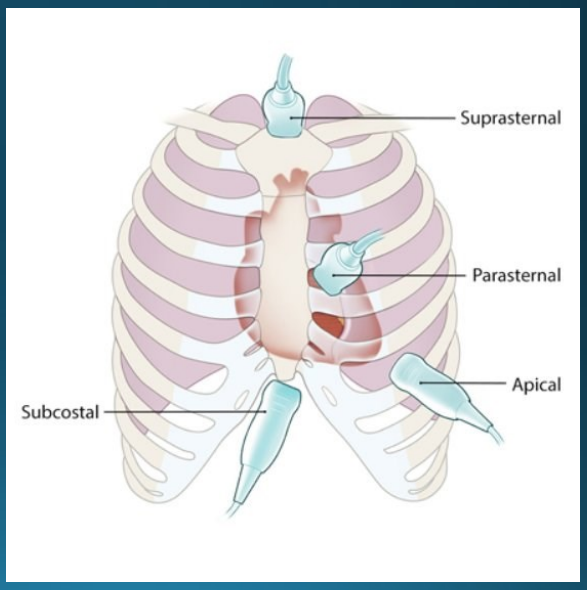

Technical

- Depth

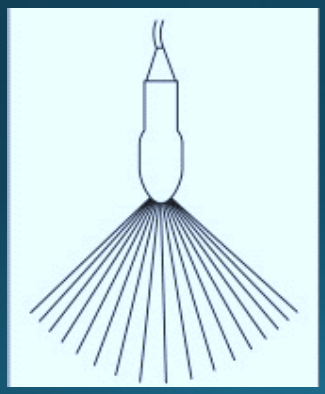

Recap

Anatomic	Physiologic	Technical
Shape: Crescentic/Triangular	Contraction patterns	Orientation (Views)
Thin wall	Load sensitivity	Retrosternal
Trabeculations	Adaptation	Near field
	Coronary Blood flow	

Goals of Assessment

1. RV size / volumes
2. RV wall thickness
3. RV systolic function
4. RV diastolic function
5. Hemodynamics

Key Windows & Views

- Parasternal:
  - PLAX
    - RV Inflow
    - RV outflow / PA
  - PSAX
- Apical
  - 4-chamber
  - RV focused 4-chamber
- Subcostal

Key Windows & Views

- Parasternal:
  - PLAX
    - RV Inflow
    - RV outflow / PA
  - PSAX
- Apical
  - 4-chamber
  - RV focused 4-chamber
- Subcostal

Parasternal

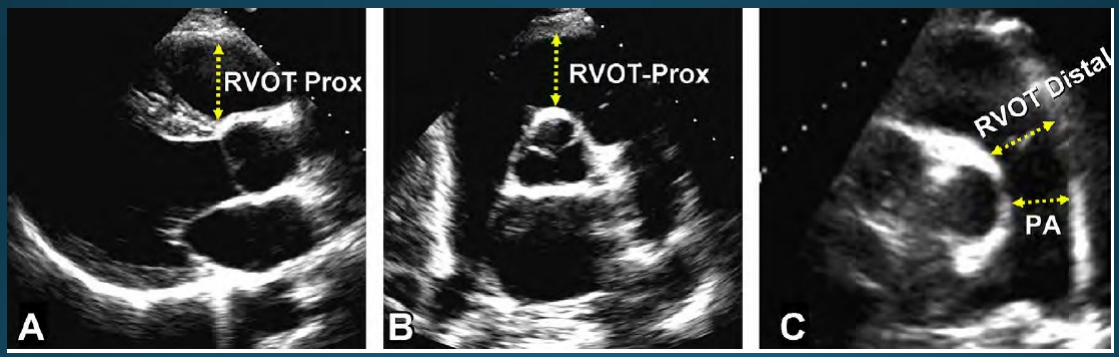

Apical

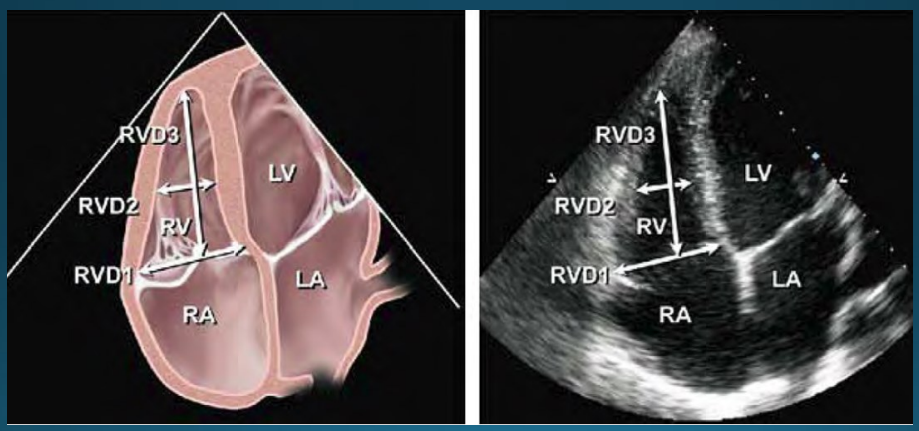

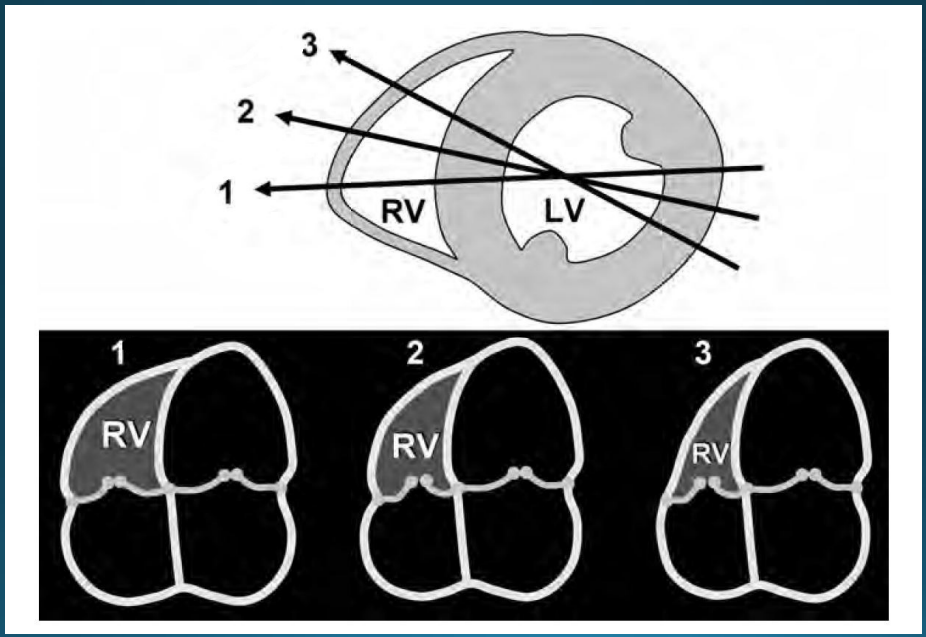

Measuring RA

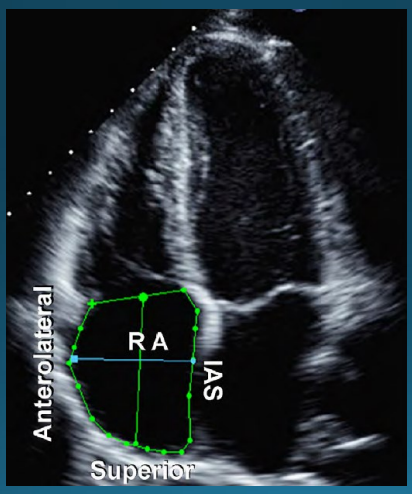

RV wall thickness

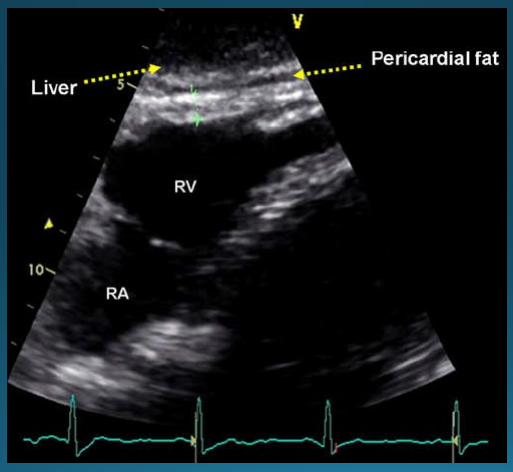

RV volumes

- 2d Methods
- 3D methods

Reference Limits

Dimensions	Abnormal
RVOT PLAX	>3.3 cm
RVOT PSAX proximal	>2.7 cm
RV basal (Mod AP4)	>4.2 cm
RV mid cavity	>3.5 cm
RA	> 5.3 /4.4 cm
RA area	>18 cm^2
RV wall Thickness (Subcostal)	>0.5 cm

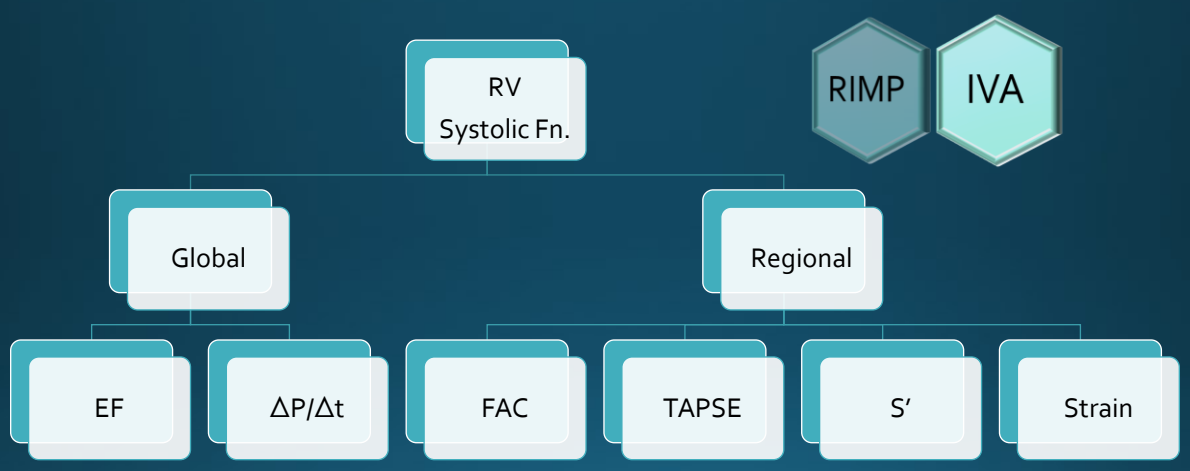

TAPSE

- Easy
- Reproducible
- Excellent agreement
- Validated outcome data
- High specificity

- Uni-dimensional
- Regional function
- Low sensitivity
- Angle dependency
- Translational motion

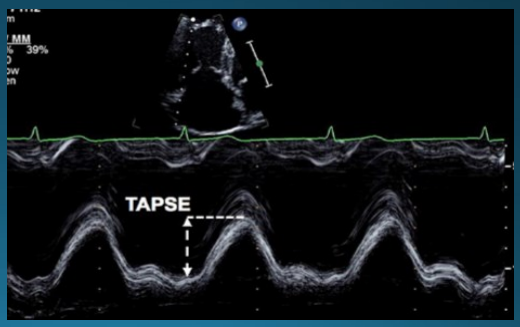

Fractional Area Change (FAC)

- Validated outcome data
- Best correlation with MRI volumes
- Longitudinal +Radial Fn.

- Less IO agreement
- Regional function
- Endocardial definition
- RV size

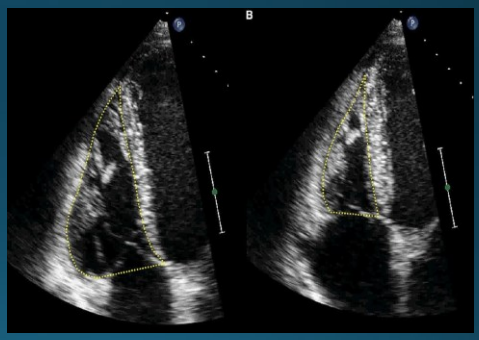

PW TD Lateral annulus velocity

- Easy
- Reproducible
- Excellent agreement
- Validated outcome data

- Regional function
- Angle dependency
- Does not work in post Card Surgery, Transplant

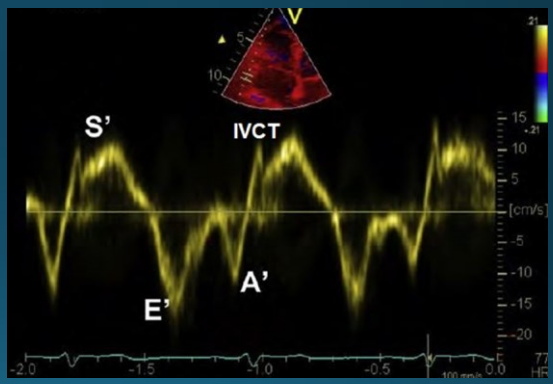

Strain imaging (speckle tracking)

- Not angle dependent
- Forgiving of 2D image quality

- Regional function
- Vendor specific
- Less validated

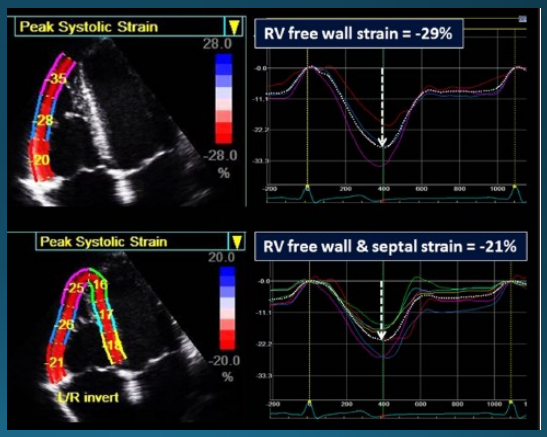

3D Volumes, EF

- Limited experience
- Not widely available
- Time consuming (offline analysis)
- Arrhythmias
- Motion
- Image quality
- Limited prognostic data

RV dp/dt

- Global Measure
- Physiologic
- Easy and reproducible
- Forgiving of 2D image quality

- Highly load dependent
- Does not work well in >moderate TR
- Limited normative data
- No prognostic data

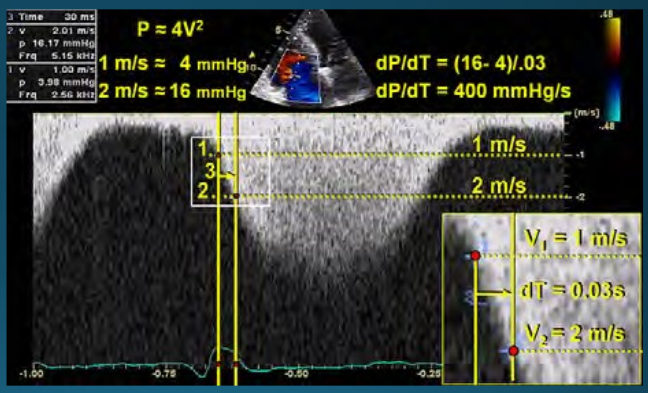

Tei Index (RIMP) & IVA

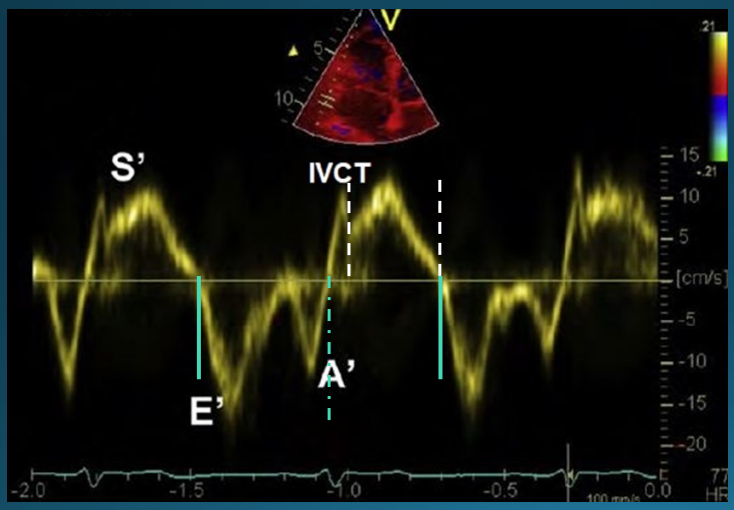

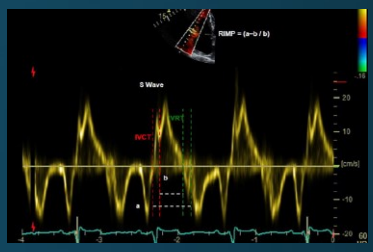

RIMP=(IVRT + IVCT)/ET

Tei Index (RIMP) & IVA

- Systolic + Diastolic
- Easy and reproducible
- Less load dependent
- No geometric assumptions

- Does not work well in ↑RAP
- Limited prognostic data

RIMP=(IVRT + IVCT)/ET

RV diastolic function

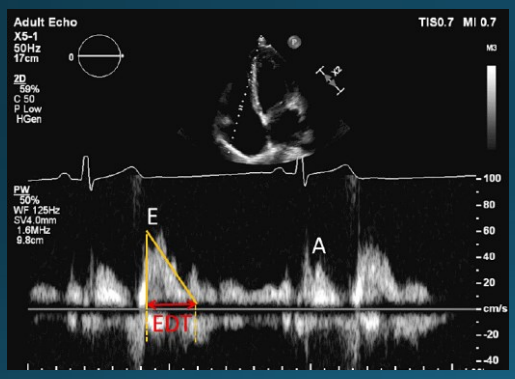

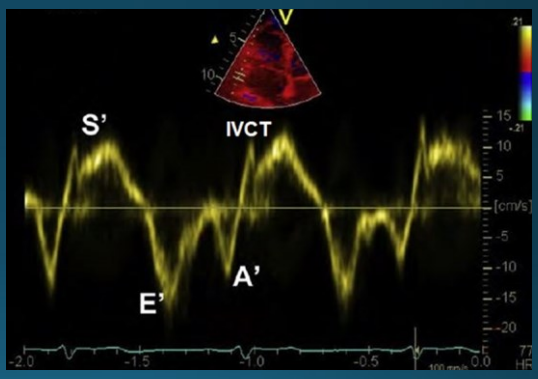

RA, IVC, Hepatic vein flow should all be an integral part of comprehensive RV assessment

Reference Limits

Function	Abnormal
Systolic (Regional)	
TAPSE	<1.6-1.7 cm
PWD TD annular systolic velocity	<9.5-10 cm/s
RV FAC	<35%
RV Strain (Mod AP4) Lateral	>-20%
Systolic (Global)	
RV EF (3 D)	<44-45%
RV dP/dt	<400 mm Hg/s

Systolo-diastolic	Abnormal
Tei index (RIMP)	
PW-TDI	>0.55
IVA: PW-TDI	>2.2 m/s²
Diastolic	>0.5 cm
E/A	<0.8->2.1
E'/A'	<0.5->1.9
E/E'	>6
DCT	<120>240 msec

RV volumes and EF vary with age and by gender dependent.
Volumes ↓and EF ↑in women & with advancing age

Task Force Criteria for ARVC

Global or regional dysfunction and structural alterations

Major
- 2D echo criteria
  - Regional RV akinaesia, dyskinaesia or aneurysm and one of the following measured at end diastole
    - PLAX RVOT $\geq$ 32 mm
    - PSAX RVOT $\geq$ 36 mm
    - Fractional area change $\leq$ 33%

Minor
- 2D echo criteria
  - Regional RV akinaesia or dyskinaesia and one of the following measured at end diastole
    - PLAX RVOT $\geq$29 to $<$ 32 mm
    - PSAX RVOT $\geq$32 to $<$ 36
    - Fractional area change $>$33% to $\leq$ 40%

Hemodynamic assessment Pulmonary Hypertension

1. RAP
2. RVSP (surrogate for PA systolic pressure)
3. Pulmonary Pressures (diastolic/mean)
4. RV stroke volume / cardiac output
5. Pulmonary vascular resistance

Hemodynamic assessment Pulmonary Hypertension

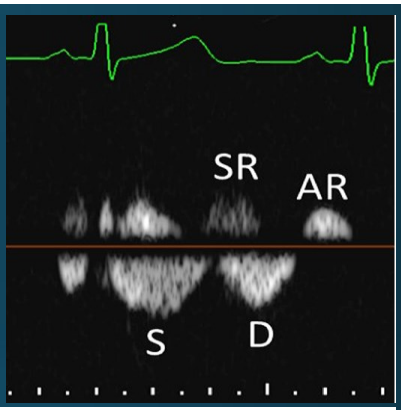

1. RAP
2. RVSP (surrogate for PA systolic pressure)

Variable	Normal (0-5 [3] mm Hg)	Intermediate (5-10 [8] mm Hg)		High (15 mm Hg)
IVC diameter	≤2.1 cm	≤2.1 cm	>2.1 cm	>2.1 cm
Collapse with sniff	>50%	<50%	>50%	<50%
Secondary indices of elevated RA pressure				• Restrictive filling • Tricuspid E/E′ > 6 • Diastolic flow predominance in hepatic veins (systolic filling fraction < 55%)

Hemodynamic assessment Pulmonary Hypertension

RVSP = $4V^2$ + RA pressure

1. RAP
2. RVSP (surrogate for PA systolic pressure)
3. Pulmonary Pressures (diastolic/mean)
4. RV stroke volume / cardiac output
5. Pulmonary vascular resistance

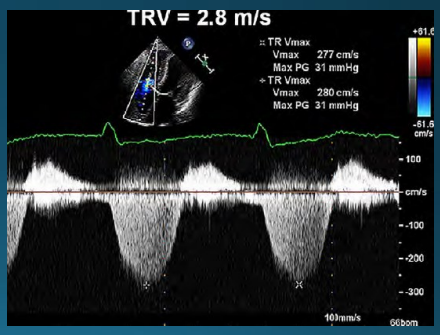

Hemodynamic assessment Pulmonary Hypertension

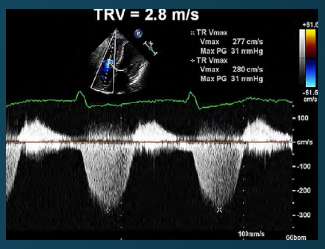

1. RAP
2. RVSP (surrogate for PA systolic pressure)
3. Pulmonary
4. RV stroke v
5. Pulmonary

RVSP = $4V^2$ + RA pressure

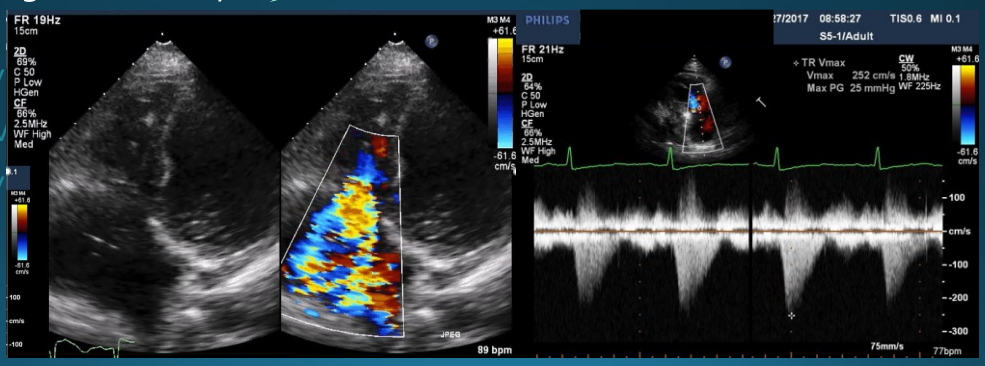

Hemodynamic assessment Pulmonary Hypertension

1. RAP
2. RVSP (surrogate for PA s pressure)
3. Pulmonary Pressures (diastolic/mean)
4. RV stroke volume / cardiac output
5. Pulmonary vascular resistance

RVSP = $4V^2$ + RA pressure

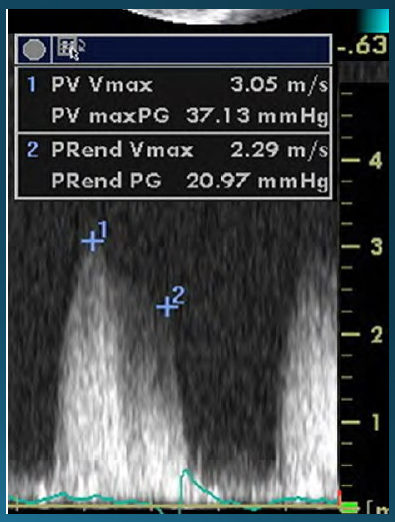

Hemodynamic assessment

1. RA
2. RV (surrogate for PA systolic pressure)
3. Pulmonary Pressures (diastolic/mean)
4. RV stroke volume / cardiac output
5. Pu

Mean PAP= 79 -(0.45 x Pulmonary Acceleration Time)

Mean PAP= Pulm DP+1/3 PP

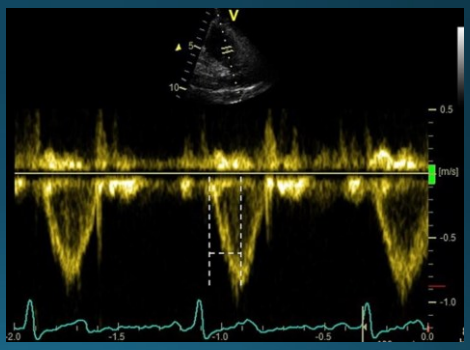

Hemodynamic assessment Pulmonary Hypertension

1. RAP
2. RVSP (surrogate for PA systolic pressure)
3. Pulmonary Pressures (diastolic/mean)
4. RV stroke volume / cardiac output
5. Pulmonary vascular resistance

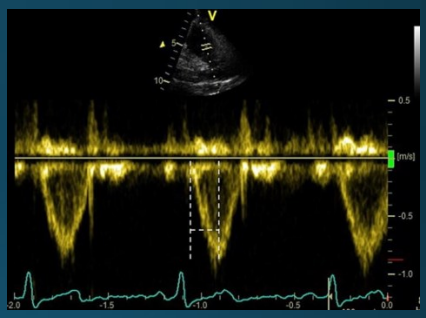

{peak TR velocity (m/s) / RVOT VTI (cm) }x 10+0.16

Recap: Key Formulae

Estimate RAP: 3, 8, 15

RVSP = $4V^2$ + RA pressure

Pulm DP = $4V^2$ (end diastolic PR)+ RA pressure

Mean PAP= Pulm DP+1/3 PP

Mean PAP= 79 -(0.45 x Pulmonary Acceleration Time)

Mean PAP = $4V^2$ (early diastolic PR)+ RA pressure

Mean PAP= 90 -(0.62 x PAT)

{TR velocity (m/s) / RVOT VTI (cm) }x 10+0.16

(TRV2/VTI) x 5

Take Home Points

- Use multiple views / measures to make qualitative/quantitative assessment
- FAC, TAPSE, S' using Tissue Doppler are the most established quantitative markers of RV function and should be performed
- Use right atrium, IVC and Hepatic Veins as an integral part of RV assessment
- Using validated formulae, Echocardiography can provide valuable insights into RV hemodynamic function & status of Pulm. vascular tree.

Thank you
Good Luck