American College of Cardiology
Iowa Chapter

# Mitral Stenosis

Echo Board Preparation Lectures Series

**PROMPORN SUKSARANJIT MD**
May 1, 2021

Image source: JACC: CASE REPORTS, VOL. 2, NO. 12, 2020
Narula et al. OCTOBER 2020: 1845–8

## Nothing to disclose

Questions: Clinical echocardiography review book (2nd edition, Allan L Klein)

# Question 1

During routine assessment of a patient with known valvular disease, the sonographer measures a mitral inflow deceleration time of 758 ms. Which of the following is a reasonable estimate of the mitral valve area?

A. 1 cm2

B. 0.3 cm2

C. 3 cm2

D. 1.5 cm2

E. 2 cm2



# Question 2

What is the correct measurement of the pressure half-time of the mitral inflow signal?

A. Trace 1

B. Trace 2

C. Trace 3

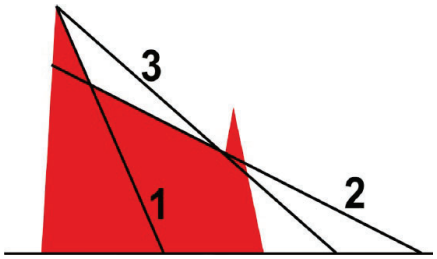

# Question 3

A 49-year-old woman presents with a history of progressively worsening dyspnea. She remembers having frequent throat infections as a child. The electrocardiogram shows atrial fibrillation with an average heart rate of 85 beats/min. A TEE is performed. Chest x-ray shows normal heart size.

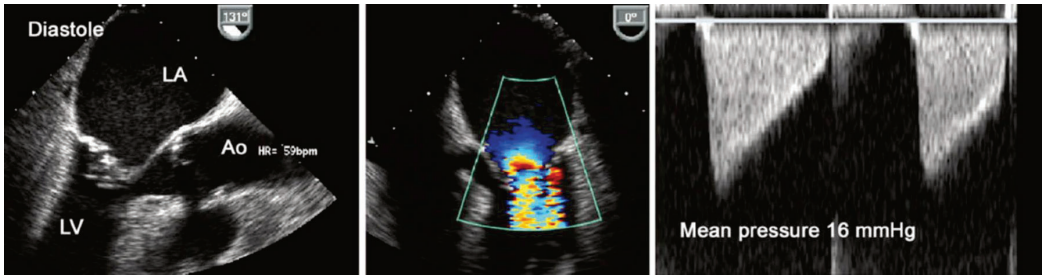


# Question 3

A 49-year-old woman presents with a history of progressively worsening dyspnea. She remembers having frequent throat infections as a child. The electrocardiogram shows atrial fibrillation with an average heart rate of 85 beats/min. A TEE is performed. Chest x-ray shows normal heart size.
Clinical examination is most likely to show:

A. Laterally displaced apical impulse.

B. Opening snap occurring late after A2.

C. Opening snap occurring early after A2.

D. Apical diastolic rumble decreasing with leg exercise.

# Question 4

A 78-year-old woman has been complaining of worsening dyspnea on exertion for the past 6 months.

She has a history of hypertension that is poorly controlled despite treatment with a diuretic, angiotensin receptor blocker and a dihydropyridine calcium channel blocker. Her primary care physician noted a murmur and requested an echocardiogram.

This shows presence of a mildly enlarged left ventricle, with calculated ejection fraction of 65%. The aortic valve is sclerotic, with a mean gradient of 10 mm Hg and moderate regurgitation. The mitral annulus and base of mitral valve leaflets are densely calcified, with a mean diastolic gradient of 9 mm Hg at a heart rate of 82 beats/min. The E velocity is 2.1 m/s, with a pressure half-time of 110 ms. The mitral valve area by planimetry in short-axis parasternal view is 1.3 $cm^2$.

IOWA

# Question 4

Which of the following statements is correct ?

A. The mitral valve area is best estimated in this patient by the pressure half-time method.

B. Mitral balloon valvuloplasty is indicated in this symptomatic patient.

C. Mitral valve replacement is indicated in this symptomatic patient.

D. Mitral stenosis severity should be reassessed after blood pressure and heart rate are better controlled.

IOWA

## Question 5

Which of the following mitral stenosis patients is likely to benefit from mitral balloon valvuloplasty?

A. Asymptomatic 29-year-old woman with a mitral mean gradient of 9 mm Hg and resting TR velocity of 4 m/s.

B. A 49-year-old man complaining of dyspnea and a mitral pressure half-time of 110 ms.

C. A 62-year-old woman complaining of dyspnea and evidence of heavily calcified mitral commissures and a mitral valve mean gradient of 12 mm Hg.

D. An asymptomatic 35-year-old woman with a mitral valve mean gradient of 12 mm Hg and a loud apical systolic murmur.



## Question 6

Which of the following echocardiographic findings are important in predicting the outcome of mitral balloon valvuloplasty?

A. Presence of significant valvular calcification.

B. Presence of significant valvular thickening.

C. Presence of significant subvalvular calcification.

D. All of the above.

E. A and B.

# Outline

- → Causes and Anatomic Presentation
- → Severity Assessment
  - Pressure Gradient
  - Planimetry
  - Pressure Half-Time
  - Continuity Equation
  - Proximal Isovelocity Surface Area (PISA)
- → Management

IOWA

# Mitral Valve

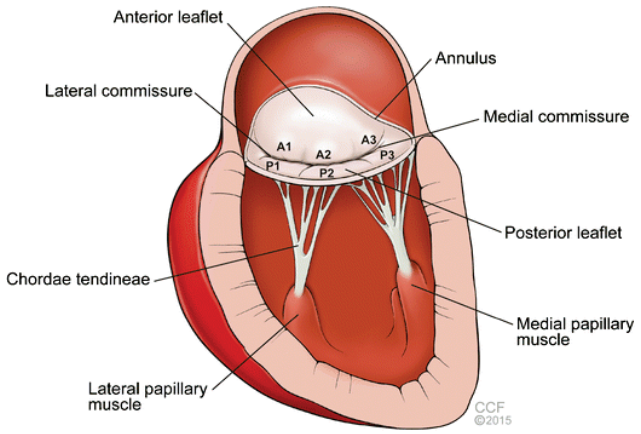


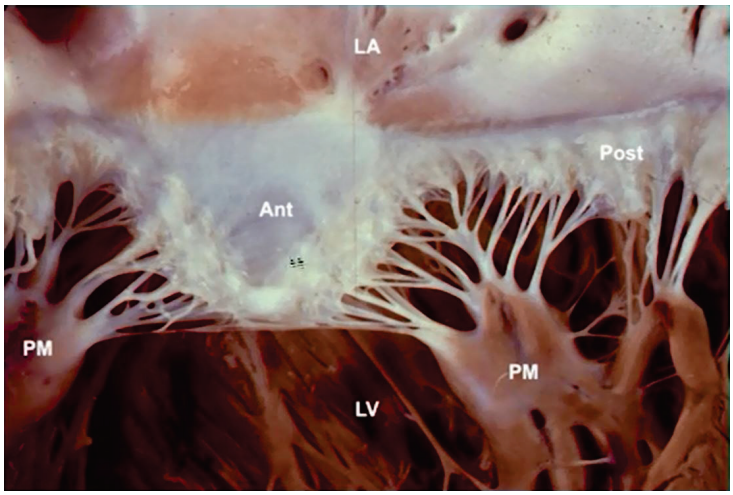


IOWA

Image source: Mitral Valve Disease: a Comprehensive Review. Curr Cardiol Rep 19, 73 (2017).

# Chronic Rheumatic Disease

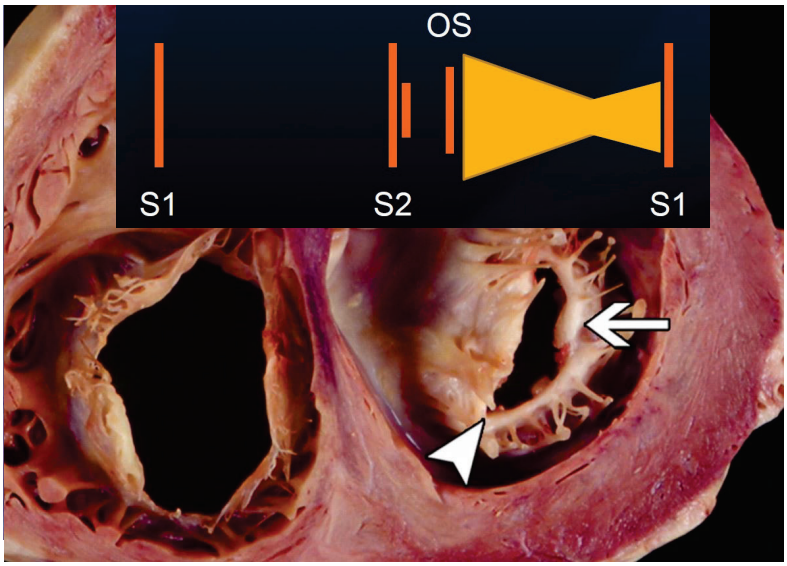


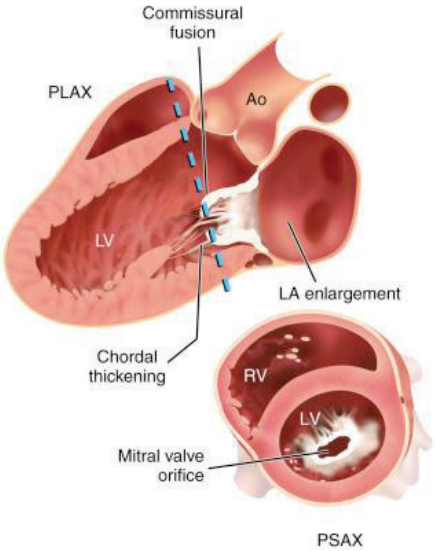


IOWA

Image source: Medsphere.Wordpress.com; Textbook of Clinical Echocardiography (Otto)

# Rheumatic Mitral Stenosis (2D)

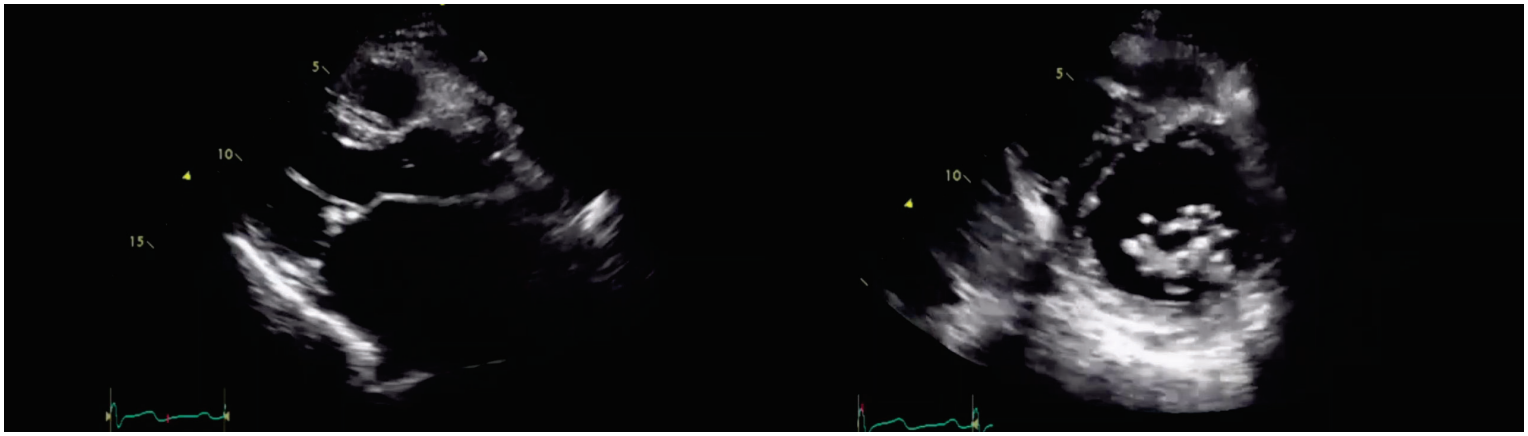

IOWA

Image source: Textbook of Clinical Echocardiography (Otto)

# Rheumatic Mitral Stenosis (M-Mode)

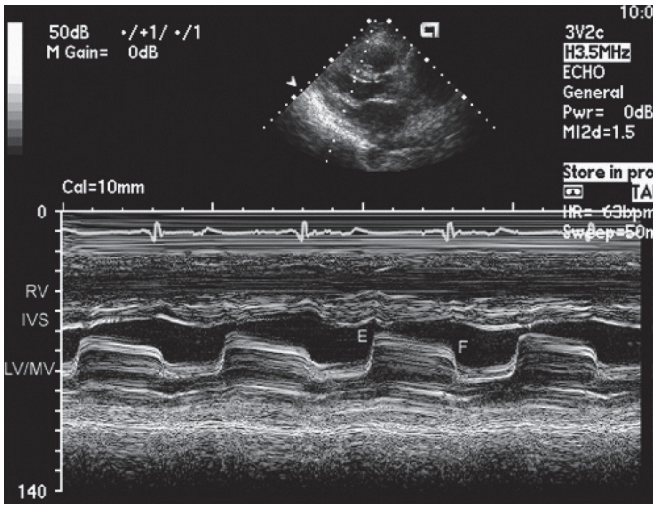


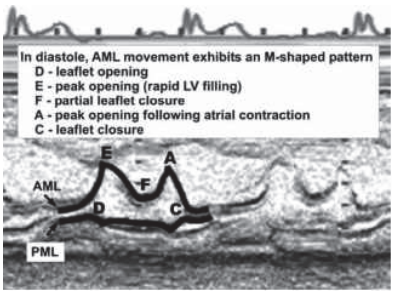


IOWA

Image source: Feigenbaum's echocardiography

# Degenerative (Calcific)

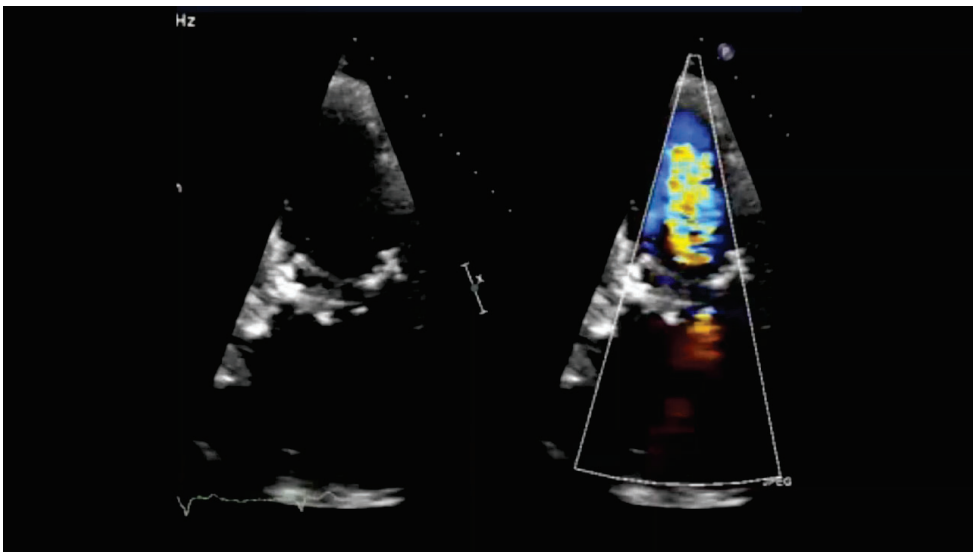


IOWA

Image source: Textbook of Clinical Echocardiography (Otto)

# Accurate measurement of the transmitral gradient in patients with mitral stenosis

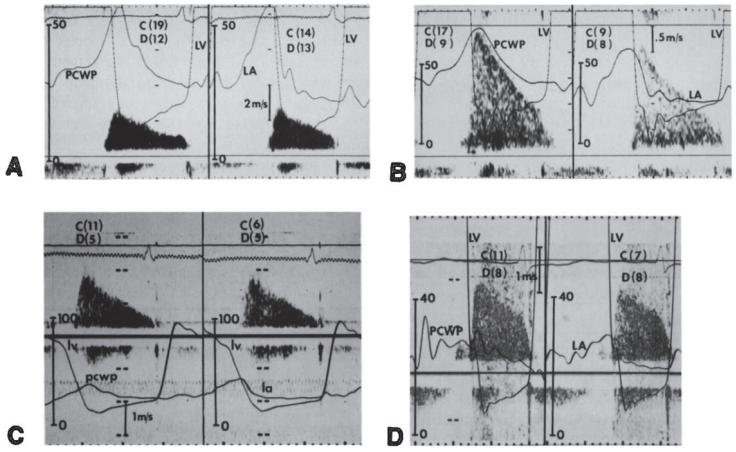


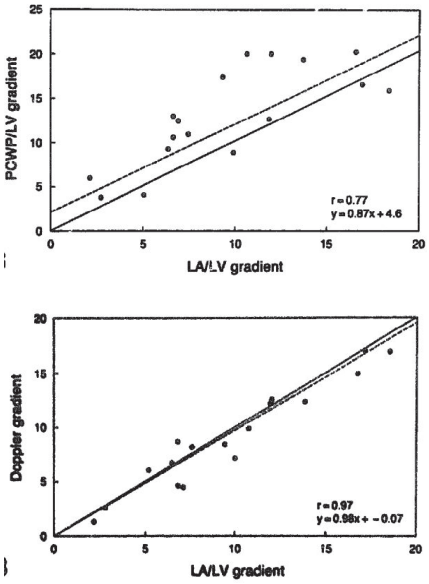


J Am Coll Cardiol. 1994; 24:152–8.

# Mean Gradient

$$\text{Mean Mitral Gradient} = \frac{4v_1^2 + 4v_2^2 + 4v_3^2 + \ldots + 4v_n^2}{n}$$

# Mean Gradient

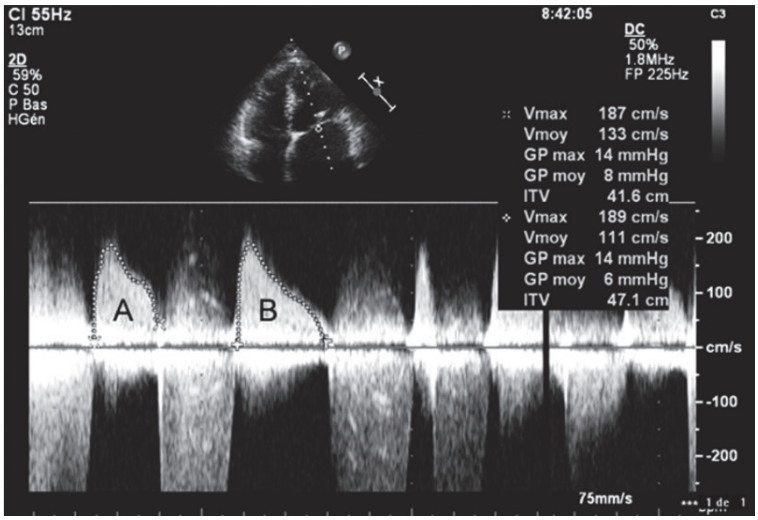


IOWA

Baumgartner et al Journal of the American Society of Echocardiography January 2009

# 2D Planimetry

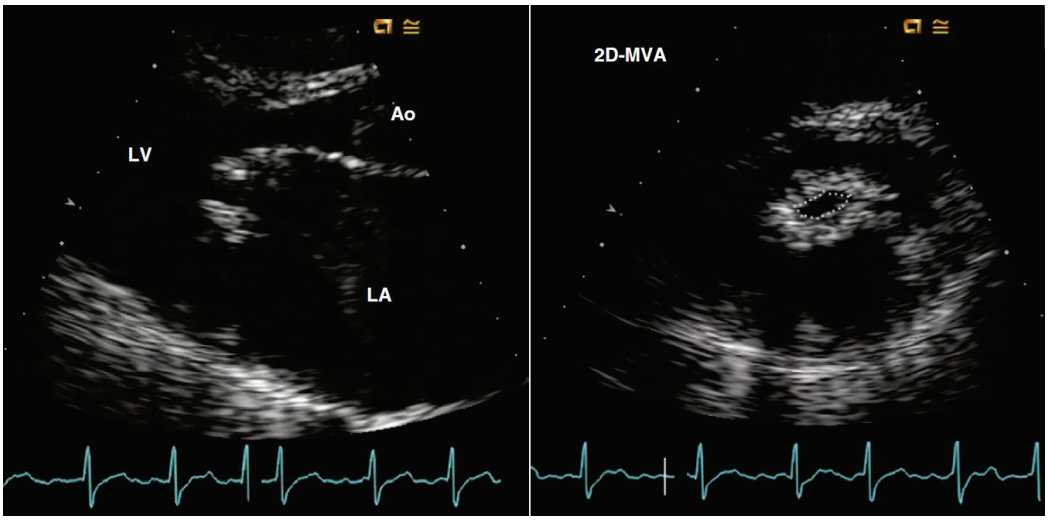


IOWA

Image source: Textbook of Clinical Echocardiography (Otto)

# Limitation of 2D Planimetry

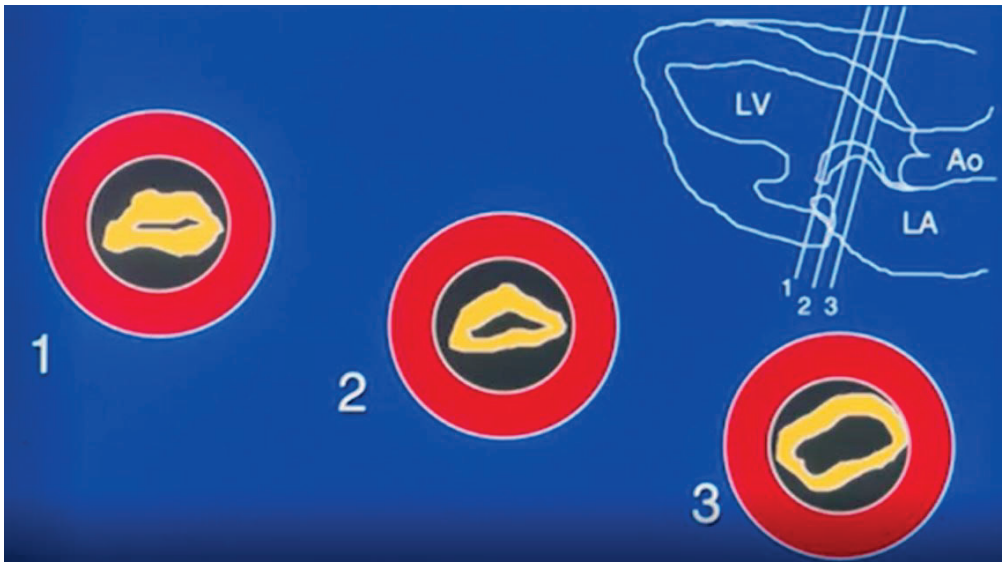


# 3D Planimetry

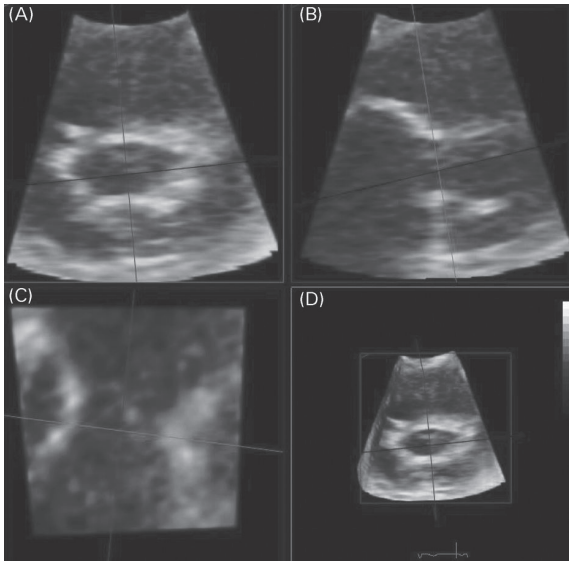


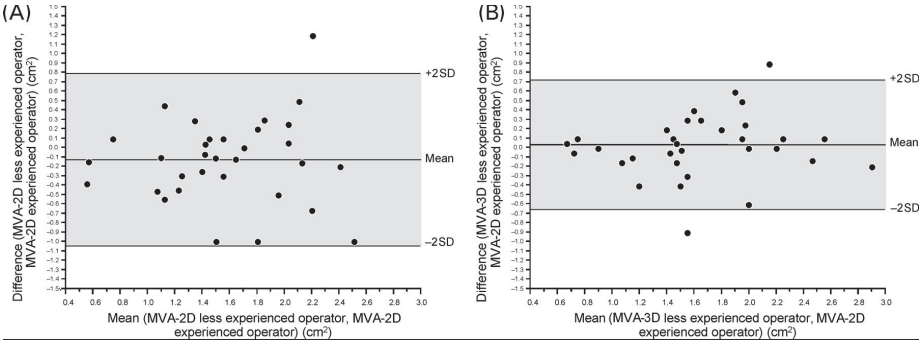

# Pressure half time

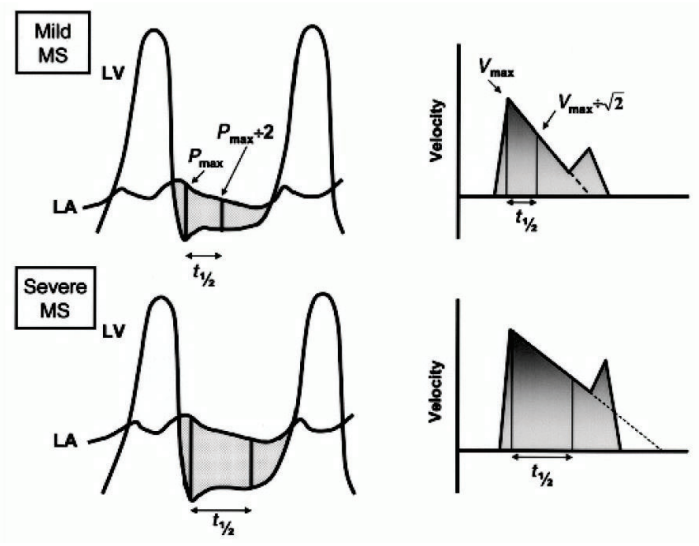


**MVA = 220/PHT**

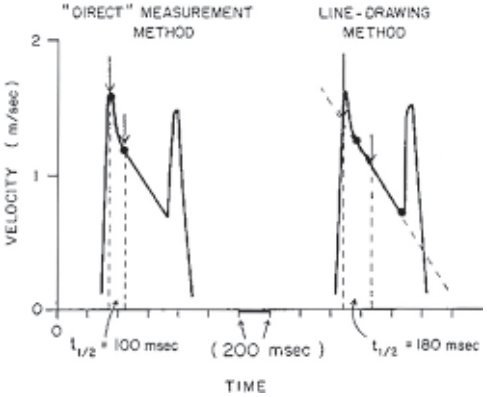




Image source: Feigenbaum's echocardiography

# Conservation of Mass Principle

## Continuity Equation

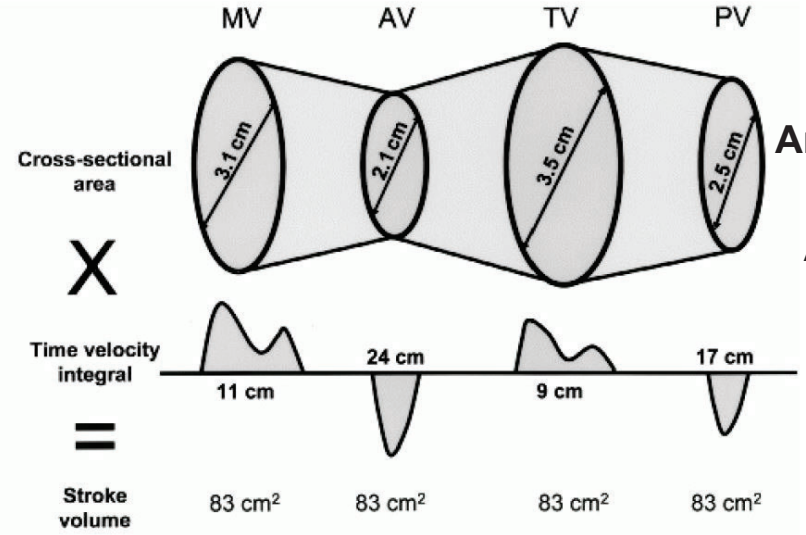


$$\text{Area}_{LVOT} \times \text{TVI}_{LVOT} = \text{Area}_{Valve} \times \text{TVI}_{Valve}$$

$$\text{Area}_{Valve} = \text{Stroke Volume} / \text{TVI}_{Valve}$$



Image source: Feigenbaum's echocardiography

# Continuity Equation

$$\text{MVA} = \frac{0.785 \times \text{Early Systole}^2 \times}{}$$

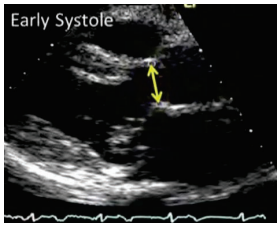


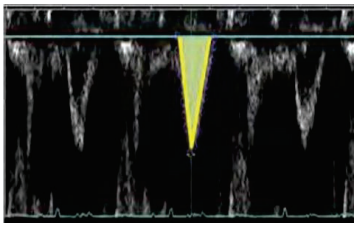

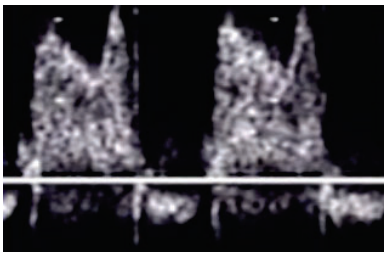

IOWA

# Proximal Isovelocity Surface Area

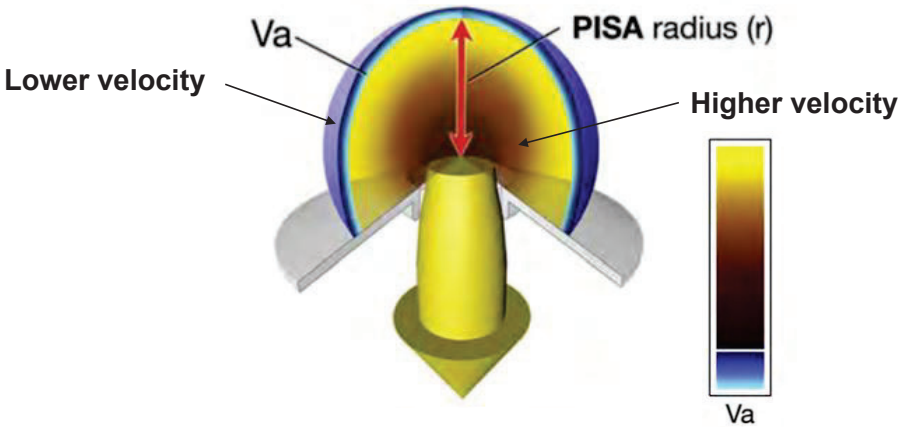


Flow = $2\pi r^2$ x Velocity (aliasing)

IOWA

Zoghbi WA, et al. J Am Soc Echocardiogr 2017; 30(4):303-371.

# PISA
## Mitral Stenosis

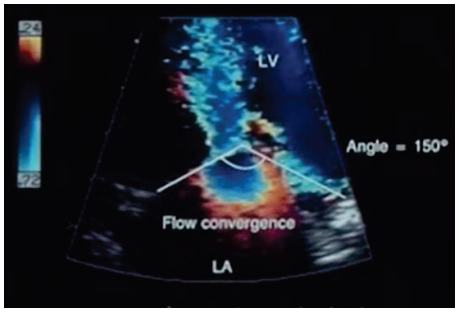


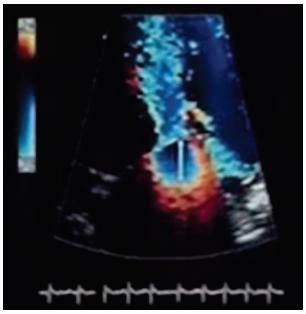

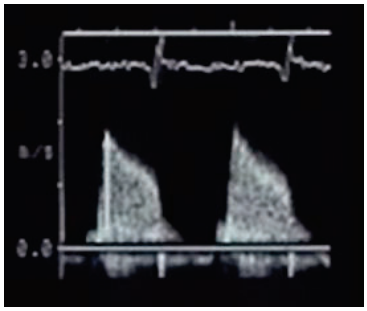

**Diastolic flow = Hemispheric flow x Constraint angle**
**= 6.28 x $r^2$ x Aliasing Velocity x α/180**

**MVA = Diastolic flow / MV V max**

IOWA

Image source: Eur Heart J 2003 Jul; 24(13): 1244-53

# Mitral Valve Area

→ Planimetry, PHT – Class 1 recommendation

→ PISA, Continuity – Class 2 recommendation

IOWA

Baumgartner et al Journal of the American Society of Echocardiography January 2009

# Stages of Mitral Stenosis

| Stage | Definition | Valve Anatomy | Valve Hemodynamics | Hemodynamic Consequences | Symptoms |
|---|---|---|---|---|---|
| A | At risk of MS | Mild valve doming during diastole | Normal transmitral flow velocity | None | None |
| B | Progressive MS | Rheumatic valve changes with commissural fusion and diastolic doming of the mitral valve leaflets<br>Planimetered mitral valve area >1.5 $cm^2$ | Increased transmitral flow velocities<br>Mitral valve area >1.5 $cm^2$<br>Diastolic pressure half-time <150 ms | Mild to moderate LA enlargement<br>Normal pulmonary pressure at rest | None |
| C | Asymptomatic severe MS | Rheumatic valve changes with commissural fusion and diastolic doming of the mitral valve leaflets<br>Planimetered mitral valve area ≤1.5 $cm^2$ | Mitral valve area ≤1.5 $cm^2$<br>Diastolic pressure half-time ≥150 ms | Severe LA enlargement<br>Elevated PASP >50 mm Hg | None |
| D | Symptomatic severe MS | Rheumatic valve changes with commissural fusion and diastolic doming of the mitral valve leaflets<br>Planimetered mitral valve area ≤1.5 $cm^2$ | Mitral valve area ≤1.5 $cm^2$<br>Diastolic pressure half-time ≥150 ms | Severe LA enlargement<br>Elevated PASP >50 mm Hg | Decreased exercise tolerance<br>Exertional dyspnea |

IOWA

2020 ACC/AHA Guideline for the Management of Valvular Heart Disease

# Exercise

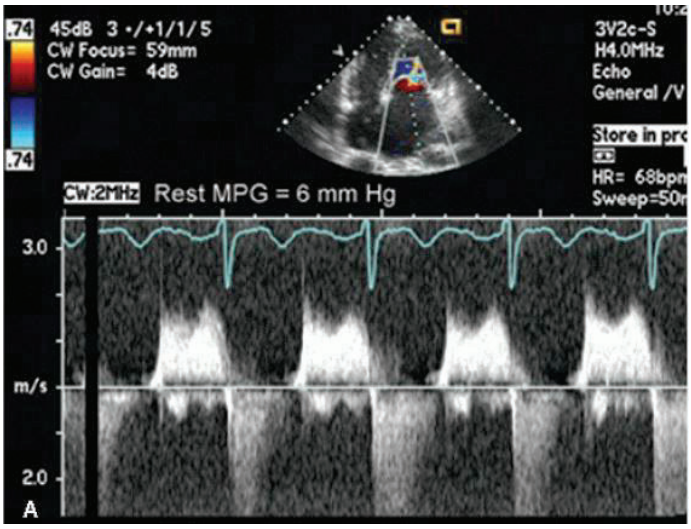


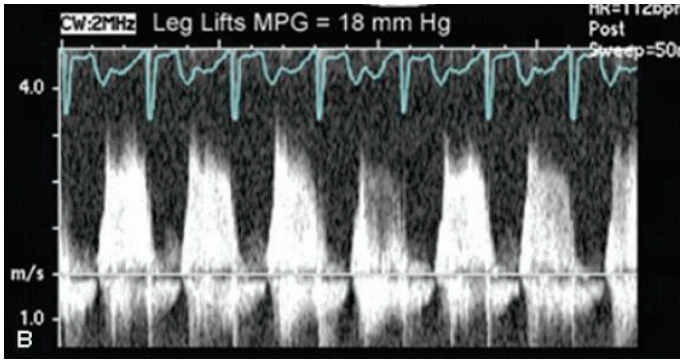


IOWA

Image source: Feigenbaum's echocardiography

# Management
## Mitral Stenosis

| Recommendation for Nonrheumatic Calcific MS | | |
|---|---|---|
| COR | LOE | Recommendation |
| 2b | C-LD | 1. In severely symptomatic patients (NYHA class III or IV) with severe MS (mitral valve area ≤1.5 cm², Stage D) attributable to extensive mitral annular calcification, valve intervention may be considered only after discussion of the high procedural risk and the individual patient's preferences and values.[1–3] |

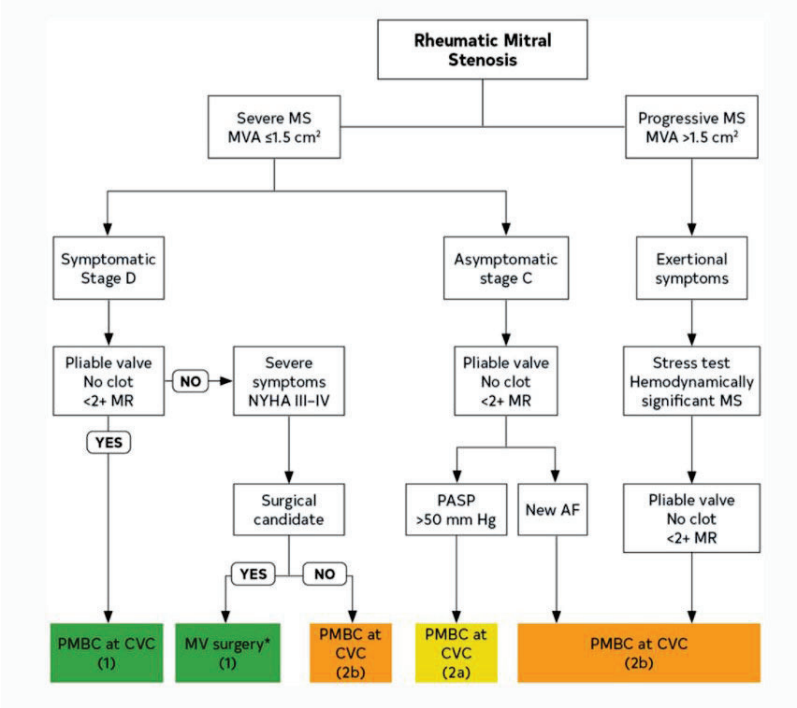


2020 ACC/AHA Guideline for the Management of Valvular Heart Disease

# Wilkins score

| Grade | Mobility | Thickening | Calcification | Subvalvular Thickening |
|---|---|---|---|---|
| 1 | Highly mobile valve with only leaflet tips restricted | Leaflets near normal in thickness (4–5 mm) | A single area of increased echo brightness | Minimal thickening just below the mitral leaflets |
| 2 | Leaflet mid and base portions have normal mobility | Midleaflets normal, considerable thickening of margins (5–8 mm) | Scattered areas of brightness confined to leaflet margins | Thickening of chordal structures extending to one-third of the chordal length |
| 3 | Valve continues to move forward in diastole, mainly from the base | Thickening extending through the entire leaflet (5–8 mm) | Brightness extending into the mid-portions of the leaflets | Thickening extended to distal third of the chords |
| 4 | No or minimal forward movement of the leaflets in diastole | Considerable thickening of all leaflet tissue (>8–10 mm) | Extensive brightness throughout much of the leaflet tissue | Extensive thickening and shortening of all chordal structures extending down to the papillary muscles |

# Predictor of Outcome After Percutaneous Mitral Balloon Valvotomy

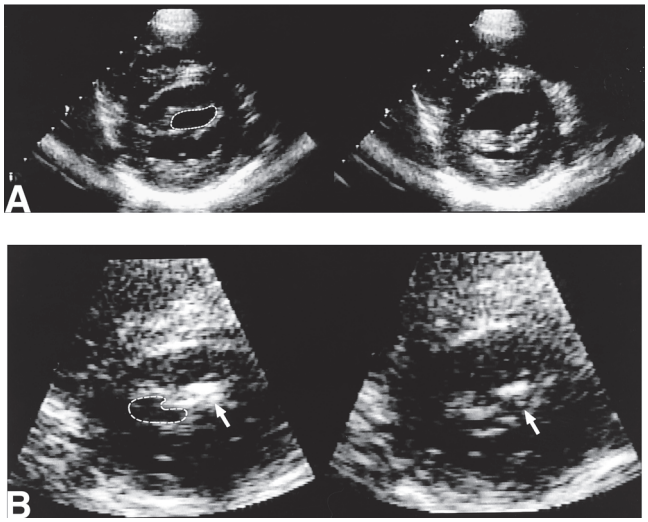


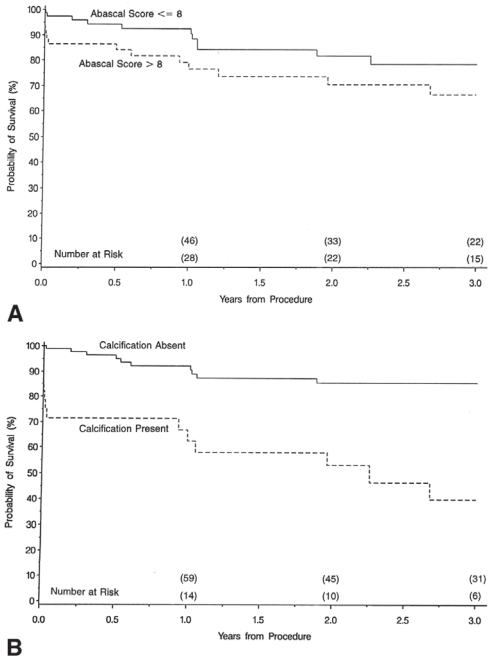


IOWA

JACC Vol. 29, No. 1 1997:175–80

# Question 1

During routine assessment of a patient with known valvular disease, the sonographer measures a mitral inflow deceleration time of 758 ms. Which of the following is a reasonable estimate of the mitral valve area?

A. 1 cm2

B. 0.3 cm2

C. 3 cm2

D. 1.5 cm2

E. 2 cm2

IOWA

# Question 2

What is the correct measurement of the pressure half-time of the mitral inflow signal?

A. Trace 1

B. Trace 2

C. Trace 3

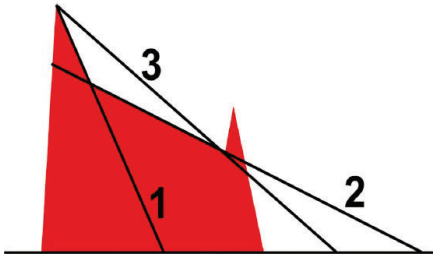


IOWA

# Question 3

A 49-year-old woman presents with a history of progressively worsening dyspnea. She remembers having frequent throat infections as a child. The electrocardiogram shows atrial fibrillation with an average heart rate of 85 beats/min. A TEE is performed. Chest x-ray shows normal heart size.

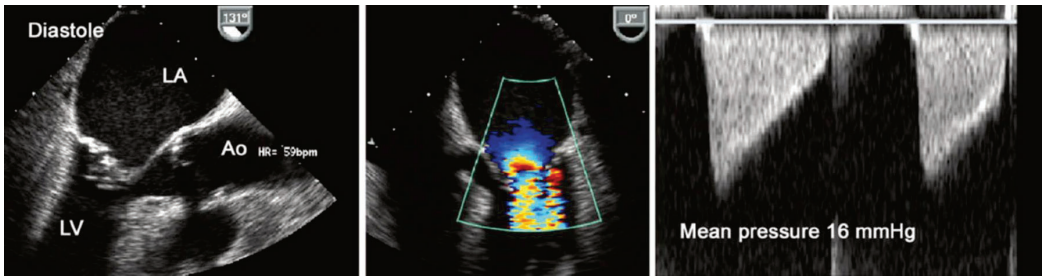


IOWA

## Question 3

A 49-year-old woman presents with a history of progressively worsening dyspnea. She remembers having frequent throat infections as a child. The electrocardiogram shows atrial fibrillation with an average heart rate of 85 beats/min. A TEE is performed. Chest x-ray shows normal heart size. Clinical examination is most likely to show:

A. Laterally displaced apical impulse.

B. Opening snap occurring late after A2.

C. Opening snap occurring early after A2.

D. Apical diastolic rumble decreasing with leg exercise.

IOWA

## Question 4

A 78-year-old woman has been complaining of worsening dyspnea on exertion for the past 6 months.

She has a history of hypertension that is poorly controlled despite treatment with a diuretic, angiotensin receptor blocker and a dihydropyridine calcium channel blocker. Her primary care physician noted a murmur and requested an echocardiogram.

This shows presence of a mildly enlarged left ventricle, with calculated ejection fraction of 65%. The aortic valve is sclerotic, with a mean gradient of 10 mm Hg and moderate regurgitation. The mitral annulus and base of mitral valve leaflets are densely calcified, with a mean diastolic gradient of 9 mm Hg at a heart rate of 82 beats/min. The E velocity is 2.1 m/s, with a pressure half-time of 110 ms. The mitral valve area by planimetry in short-axis parasternal view is 1.3 $cm^2$.

IOWA

## Question 4

Which of the following statements is correct ?

A. The mitral valve area is best estimated in this patient by the pressure half-time method.

B. Mitral balloon valvuloplasty is indicated in this symptomatic patient.

C. Mitral valve replacement is indicated in this symptomatic patient.

D. Mitral stenosis severity should be reassessed after blood pressure and heart rate are better controlled.



## Question 5

Which of the following mitral stenosis patients is likely to benefit from mitral balloon valvuloplasty?

A. Asymptomatic 29-year-old woman with a mitral mean gradient of 9 mm Hg and resting TR velocity of 4 m/s.

B. A 49-year-old man complaining of dyspnea and a mitral pressure half-time of 110 ms.

C. A 62-year-old woman complaining of dyspnea and evidence of heavily calcified mitral commissures and a mitral valve mean gradient of 12 mm Hg.

D. An asymptomatic 35-year-old woman with a mitral valve mean gradient of 12 mm Hg and a loud apical systolic murmur.

# Question 6

Which of the following echocardiographic findings are important in predicting the outcome of mitral balloon valvuloplasty?

A. Presence of significant valvular calcification.

B. Presence of significant valvular thickening.

C. Presence of significant subvalvular calcification.

D. All of the above.

E. A and B.

IOWA

# Questions ?

@PSuksaranjitMD

Promporn-Suksaranjit@uiowa.edu

IOWA